Visualization of Fiber Structure in the Left and Right Ventricle of a Human Heart

Damien Rohmer, Arkadiusz Sitek, Grant T. Gullberg

Ernest Orlando Lawrence Berkeley National Laboratory, Life Sciences Division, 1 Cyclotron Road, Berkeley, CA 94720, USA.

Running Title: Fiber Structure in the Heart
Subject Codes: 124, 104
Total Word Count: 1065
Number of Figures: 2

Corresponding Author:

Grant T. Gullberg, Ph.D.
Lawrence Berkeley Laboratory,
1 Cyclotron Road, MS55R0121
Berkeley, CA 94720, USA.
Email: GTGullberg@lbl.gov
Phone: 510 486-7483

Abstract

The human heart is composed of a helical network of muscle fibers. Anisotropic least squares filtering followed by fiber tracking techniques were applied to Diffusion Tensor Magnetic Resonance Imaging (DTMRI) data of the excised human heart. The fiber configuration was visualized by using thin tubes to increase 3-dimensional visual perception of the complex structure. All visualizations were performed using the high-quality ray-tracing software POV-Ray. The fibers are shown within the left and right ventricles. Both ventricles exhibit similar fiber architecture and some bundles of fibers are shown linking right and left ventricles on the posterior region of the heart.

The fiber structure in the heart myocardium is known to have a helical orientation throughout the heart wall. The fiber direction can be determined experimentally by the technique of Diffusion Tensor Magnetic Resonance Imaging (DTMRI) which is used to measure the three-dimensional distribution of the diffusion tensor for water in biological tissues. The fiber directions are determined by estimating the principal directions of the diffusion tensor distribution. A normal human heart was excised and placed in a container filled with perluoropolyether. A DTMRI acquisition was performed at Johns Hopkins Medical Center using a 4-element phased array coil on a 1.5 T (GE CV/I MRI Scanner). The diffusion tensor data were made available on the internet at www.ccbm.jhu.edu by Drs. Patrick A. Helm and Raimond L. Winslow at the Center for Cardiovascular Bioinformatics and Modeling and by Dr. Elliot McVeigh at the National Institute of Health[1]. The data consist of a voxelized distribution of the diffusion tensor where each voxel is 429.7 μm × 429.7 μm × 1000 μm. Anisotropic filtering was performed on the data to smooth the principle directions by using the moving least squares (MLS) method[2].

Fiber tracking was then performed on the filtered data by eigenvalue decomposition of the diffusion tensor distribution[3]. The eigenvector linked to the largest eigenvalue corresponded to the averaged direction of all fibers in a single voxel[1]. The fiber paths were reconstructed by integration along these directions. The tracking started at seed points equally spaced on a Cartesian grid and within a mask that delineated both right ventricle (RV) and left ventricle (LV). Tracking was terminated when the track left the mask.

The visualization was performed by using tube surfaces rendered by the open source ray tracing software, POV-Ray. The ray tracing algorithm enables one to visualize lighted, shaded surfaces. The red color encodes a positive helical orientation (clockwise rotation from bottom to top) that dominates the epicardium. The opposite orientation is encoded with the white color that can be seen primarily in the endocardium.

The change of fiber directions from epi- to endocardium is clearly seen in the LV (Figure 1A, 2A) where the fibers exhibit a change of their helical directionality through the heart wall. The RV shows a helical configuration changing from epi- to endocardium although it is not as clear as for the LV because the wall of the RV is not as thick. The junction between RV and the pulmonary artery is recognized on the anterior wall of the RV where the fibers wrap around this connection (Figure 1A, 2A). Continuity between fibers in the RV and LV are noticed in the posterior region (Figure 1B, 2C). The fibers in the posterior wall of the RV pass smoothly to the epicardial posterior region of the LV and continue through the wall to the lateral region. There is no apparent connection between the fibers in the septal wall of the LV and RV (Figure 2D). Movies are also provided as supplementary data to enhance the depth perception of the previous images by rotation of the images.

Acknowledgments

This work was supported by NIH Grant R01 EB000121 and U.S. Department of Energy (DOE) under contract DE-AC02-05CH11231. The authors acknowledge Drs. Patrick A. Helm and Raimond L. Winslow at the Center for Cardiovascular Bioinformatics and Modeling and Dr. Elliot McVeigh at the National Institute of Health for providing the data. The data may be accessed on the internet at www.ccbm.jhu.edu.

References

1. Scollan DF, Holmes A, Winslow R, Forder J. Histological validation of myocardial microstructure obtained from diffusion tensor magnetic resonance imaging. *Am J Physiol*. 1998;275:2308-18.

2. Zhukov L, Barr AH. Oriented tensor reconstruction: Tracing neural pathways from diffusion tensor MRI. *IEEE Proceedings of the Conference on Visualization.* 2002;21:387-94.

3. Rohmer D, Sitek A, Gullberg GT. Reconstruction and visualization of fiber and sheet structure with regularized tensor diffusion MRI in the human heart. Lawrence Berkeley National Laboratory Publication. LBNL-60277.

Figures Captions:

Figure 1: Results of fiber tracking visualized for the right ventricle (RV) and the left ventricle (LV). A, Anterior view of the heart. The change of helical orientation is clear for the LV going from a clockwise rotation (our convention) on the epicardium (red color) to a counterclockwise rotation on the endocardium. The RV also shows the same structure although not as clearly as the LV. The junction between the pulmonary artery and the RV is seen as a circular "hole" in the RV. B, Posterior view of the heart. The fiber links between RV and LV is clear for the epicardium. Artifacts due to noise are seen in the apex. (High resolution movies are available online as supplementary data.)

Figure 2: A, A view from the base. The blue square region delineates the junction between the LV and the RV. This region was used to seed and generate fibers which are visualized in three views indicated by the eye symbols. B, The junction seen from the interior of the LV. The fibers of the endocardial LV pass smoothly to the posterior region of the septum. C, Fiber tracks in the cut section viewed from the posterior region of the ventricles. The endocardial fibers coming from the RV are connected to fibers in the LV. D, Fiber tracks in the cut section viewed from the interior of the RV. No obvious link between septum and endocardial fibers of the RV is seen. (High resolution movies are available online as supplementary data.)

Figure 1

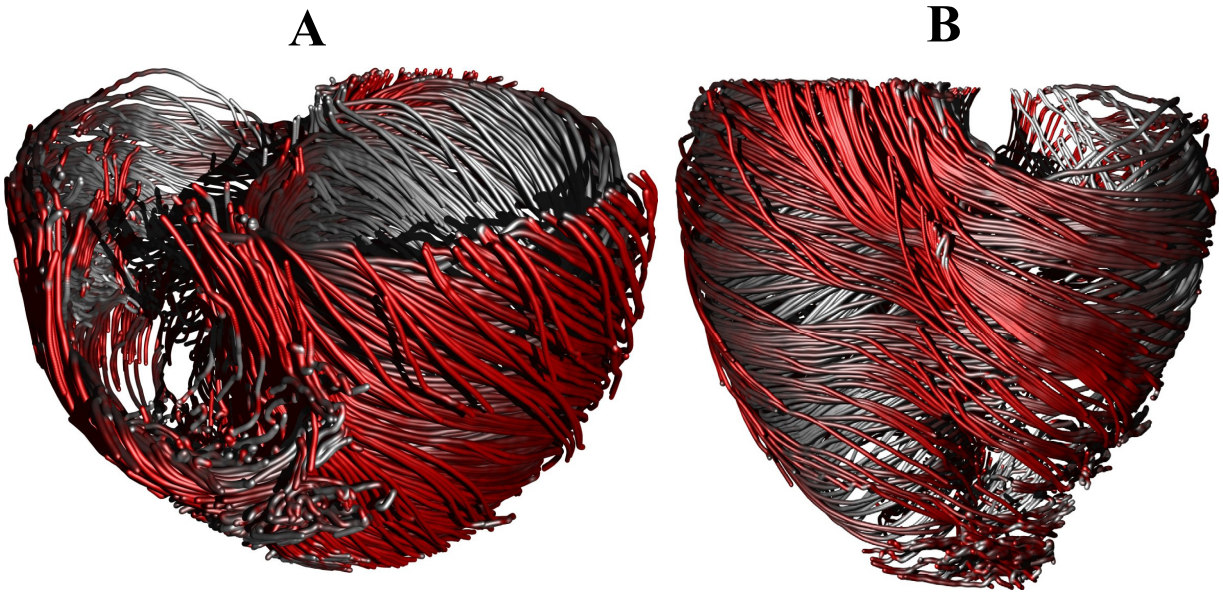
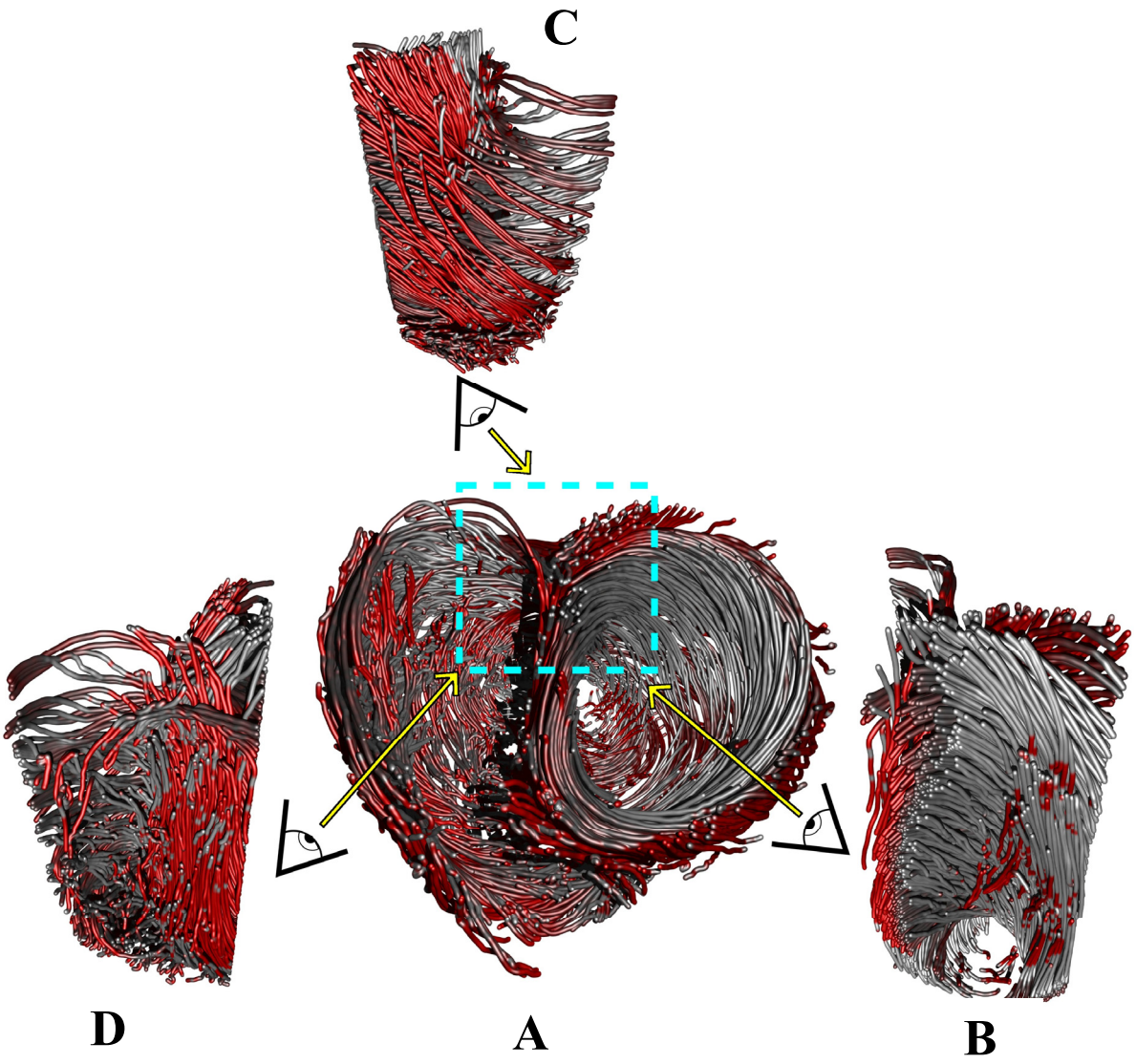
Figure 2