UCRL-11823
c.2

University of California

Ernest O. Lawrence Radiation Laboratory

APPLICATIONS OF THE SCINTILLATION CAMERA

TWO-WEEK LOAN COPY

This is a Library Circulating Copy which may be borrowed for two weeks. For a personal retention copy, call Tech. Info. Division, Ext. 5545

Berkeley, California

UCRL-11823
c.2

DISCLAIMER

This document was prepared as an account of work sponsored by the United States Government. While this document is believed to contain correct information, neither the United States Government nor any agency thereof, nor the Regents of the University of California, nor any of their employees, makes any warranty, express or implied, or assumes any legal responsibility for the accuracy, completeness, or usefulness of any information, apparatus, product, or process disclosed, or represents that its use would not infringe privately owned rights. Reference herein to any specific commercial product, process, or service by its trade name, trademark, manufacturer, or otherwise, does not necessarily constitute or imply its endorsement, recommendation, or favoring by the United States Government or any agency thereof, or the Regents of the University of California. The views and opinions of authors expressed herein do not necessarily state or reflect those of the United States Government or any agency thereof or the Regents of the University of California.

Rept. submitted for publication in
Nucleonics.

UCRL-11823

UNIVERSITY OF CALIFORNIA
Lawrence Radiation Laboratory
Berkeley, California

AEC Contract No. W-7405-eng-48

APPLICATIONS OF THE SCINTILLATION CAMERA

H. O. Anger, D. C. Van Dyke, A. Gottschalk,
Y. Yano, and L. R. Schaer

November 1964

UCRL-11823

APPLICATIONS OF THE SCINTILLATION CAMERA

H.O. Anger, D.C. Van Dyke, A. Gottschalk, Y. Yano, and L.R. Schaer

Donner Laboratory of Medical Physics and Biophysics,
University of California, Berkeley, California

This work was done under contracts with the U. S. Atomic Energy Commission

The scintillation camera has been described in a number of recent articles (1-5). In this article, the emphasis will be on the capabilities of the instrument, how it is operated, and the results obtained in clinical diagnosis, clinical research, and basic research.

¶ The scintillation camera is a non-scanning electronic instrument for producing pictures of the distribution of gamma-ray and positron emitting nuclides *in vivo*. Over the past few years, it has been developed until it is superior in many ways to medical radioisotope scanners. It is being used for nearly all the purposes of conventional scanners, such as the liver, kidneys, thyroid, spleen, brain tumors, etc., as well as several new uses described in this article.

One of the most important advantages of the scintillation camera, compared to scanners, is its higher sensitivity. Usually pictures can be taken in 1/10 the usual scanning time. Shorter exposure times encourage the use of oblique and reverse views (6), thus improving the diagnostic accuracy of the examinations. The shorter exposure times are also an economic advantage, because more patients can be examined on a given instrument per day. It is also important if the patient is seriously ill.

In some instances, the higher sensitivity of the scintillation camera permits reducing the radioisotope dosage. Alternately the picture quality can be improved by retaining the regular exposure and dosage factors. A greater number of dots are then recorded in the pictures and their apparent resolution and certainty is improved because of the reduction in statistical variations.

The scintillation camera has a further unique advantage. Unlike scanners that examine the subject a point at a time, the camera is sensitive to all points in its field of view during the entire exposure time. Sequences of still pictures and time-lapse motion pictures can be easily taken. When the counting rate is high enough, the exposure times can be as short as one second per picture or less. Dynamic studies of organ functions are among the most interesting potential uses of the scintillation camera.

Another important property of the scintillation camera is that numerical data can be obtained from any area of the picture by the use of auxiliary equipment. The method will be described in detail in another publication,

but briefly it consists of recording all the picture information on magnetic tape during the examinations, then selecting an area of an organ by referring to the picture obtained, making a paper mask to correspond to that area, and playing back the magnetic tape while detecting and counting all dots appearing within the masked area. A curve of count rate in the desired area versus time is plotted automatically.

The scintillation camera has an important area of usefulness for which scanners have been only sparingly employed, namely research into the behavior of tagged compounds in both animals and humans (7). The shorter exposure times, good resolution, and adaptability to dynamic studies make the scintillation camera particularly valuable for this application. Examples of this use are shown in this article.

Brief Description of the Camera

The scintillation camera used to obtain the pictures shown in this article is essentially the one described in a recent article in Nucleonics (1). It employs an 11 1/2-inch diameter by 1/2-inch thick sodium iodide crystal viewed by a hexagonal array of nineteen 3-inch diameter multiplier phototubes. Scintillations produced in the crystal by gamma rays are displayed on an image-readout oscilloscope as bright flashes of light that correspond in position with the original scintillations. The method by which the scintillations in the crystal are reproduced on the oscilloscope is described in other articles (1, 8). The flashes are recorded during a period of time, usually on Polaroid film. The 1000 to 10,000 or more dots that appear on the developed film form an image of the radioactive subject.

Pulse-height selection is employed so that only those scintillations that fall within a narrow range of brightness are reproduced in the image-readout oscilloscope. The result is that most background dots due to stray and scattered gamma rays are eliminated.

Images of gamma-ray emitting subjects are projected onto the scintillator either by means of pinhole collimators or multi-channel collimators. Pinhole collimators give the best combination of resolution and sensitivity for small objects such as the thyroid gland. Multichannel collimators give the best combination for larger subjects such as the brain, liver, etc. Other characteristics of each of these collimators have been described previously (2).

Multichannel collimators are characterized by a certain efficiency, resolution, and maximum gamma-ray energy. These characteristics are determined by the hole diameter, length, septal thickness and septal material. Two different multichannel collimators are most frequently used with the scintillation camera. One is a high-resolution 1165-hole collimator designed for use with medium-energy gamma rays, such as I^{131}, Hg^{203}, Cr^{51}, Se^{75}, etc. (Collimator A of Reference 2). The other is a high-resolution 4000-hole collimator made of lead foil and balsa wood, and designed for use with lower-energy gamma rays, such as Tc^{99m}, I^{123}, Ce^{139}, etc. The 1165-hole collimator can also be used with low-energy gamma-ray emitters, but the specially designed 4000-hole collimator provides higher sensitivity and equal or better resolution.

Positron Emitters

Images of positron emitters are produced by coincidence detection of the gamma-ray pairs that are produced by positron annhilation. The gamma ray collimators are not used, the patient is positioned as close to the image detector as possible, and "collimation" is achieved by the positron focal detector located below the patient. The principle of operation of this detector has been described previously (1, 9). A new model is now in use which has a single 9 x 1 1/2-inch crystal viewed by 7 multiplier phototubes. The detection efficiency is the same as the previous focal detector which employed 19 separate scintillation counters. However, the new detector is simpler and the resolution is better. The pulse-height resolution of the new focal detector is excellent.

This more complicated method of collimation is used for positron emitters because of the higher resolution and sensitivity achieved. However, the positron mode of operation has an inherent limitation, because very high counting rates are produced in the image detector when relatively small amounts of activity are near the image detector. About 50-100 μc in the immediate vicinity of the image detector is the present limit. However, this amount is large enough to give excellent pictures with a few minutes exposure. It may be increased by improvements in the speed of the electron circuits.

An advantage of the positron coincidence mode of operation is that the background is only a few counts per hour, thus permitting overnight exposures of immobilized animals and organs *in vitro* that contain very small amounts of activity.

and is to be rejected by the pulse-height selector, appears as the broad line below the photopeak line.

All pulses that pass through the pulse-height selector turn off the beam of the window-scope cathode-ray tube momentarily. The result is a dark area within the pattern that corresponds with the pulse-height selector window. By varying the gain of the amplifier circuits and the width of the pulse-height selector window, the photopeak line can be made to coincide exactly with the window. For the positron mode of operation, this adjustment must be made for both the image and focal detectors.

When the organ to be imaged covers most of the field of the camera, attention must be paid to accurate positioning of the patient. The positioning can sometimes be accomplished by looking at the image-read out oscilloscope screen. For this purpose, a long-persistance screen on the cathode-ray tube is helpful because the dots remain visible for a longer time. A memory-type oscilloscope is ideal (4), because each dot remains in view indefinitely. If the above method is not used, short test exposures lasting one minute or less on Polaroid film will indicate whether the subject is in a position to obtain the best pictures. The most satisfactory method used so far to correlate pictures of active organs with other nearby parts of the patient's anatomy is to place radioactive marker sources on the patient that show in the pictures. By this method, the costal margin can be indicated in pictures of the liver, specific vertebrae marked in pictures of the kidneys, etc. Small 1-μc sources of Ba^{133} are used for most gamma-ray emitting subjects and Ge^{68} sources for positron emitting subjects.

Proper exposure of the recording film is easily obtained. If negative film is used, the exposure time and activity of the subject is not critical, provided a low-contrast, long-scale film such as Kodak Commercial film is used. Such images usually require some degree of contrast enhancement.

If the rapid-development advantage of Polaroid film is wanted, proper exposure of the image is more critical, since Polaroid film inherently has moderately high contrast. However, the problem is easily solved with the multilens scope camera described previously (11). The flashes appearing on the image-readout oscilloscope are photographed over a period of time by a 6-lens scope camera. The six small lenses with progressively smaller f-stops produce 6 small images of the subject on a single piece of Polaroid film. Even though the exposure time and activity in the subject vary over wide limits,

one of the images is almost certain to be correctly exposed. The best-exposed image is then copied in an enlarging copier to provide pictures for the patient's chart or other records. Polaroid film, when developed for 20 seconds, has enough inherent contrast that no further contrast enhancement is necessary.

Dot Diffusion

When interpreting pictures from the scintillation camera, it is helpful to view them through a diffusion filter (11). The filter converts variations in the number of dots per unit area to different shades of grey. It blurs the distracting dot patterns so they are no longer visible, and leaves the gross variations intact. This technique is especially valuable for persons who have not had experience in the interpretation of scans. Familiar patterns in the subject became instantly recognizable through the filter, yet there is no apparent loss of useful resolution. In fact, important details have been seen with the filter when they were missed without it. A satisfactory filter consists of a piece of Tru-Site Picture Framing Glass (Dearborn Glass Co., Bedford Park, Illinois). Strong glare-free illumination helps the observer to see small differences in dot density.

Clinical Applications

A typical liver study is shown in Fig. 3 A. Eighty microcuries of I^{131} Rose Bengal were injected in a 160 lb man and 40 minutes later an 8-minute anterior exposure was taken. A defect that corresponds in location with a palpable mass is visible at the lower margin. The patient had a cancer in the large intestine removed 1 year previously. The picture shown in Fig. 3 B is a diffused copy of Fig. 3 A. The defect is more easily seen and the background is eliminated. The entire liver of normal adults can usually be imaged within the 9-inch diameter field. Enlarged livers require two or more fields.

Patency of the common bile duct can be demonstrated by the appearance of I^{131} Rose Bengal in the intestine. An example was shown recently in Nucleonics (1) where a series of pictures showed movement of the nuclide in the intestine.

Stop-Motion Scintiphotography of the Kidneys

Excellent pictures showing the renal parenchyma can be taken in 5-minutes when 100 μc of Hg^{203} Neohydrin are administered. Examples have been given in other articles (1,2,7).

Stop-motion scintiphotography demonstrating the function of the kidneys with I^{131} hippuran is shown in Fig. 4. The patient is first given 10-100 μc of Hg^{203} Neohydrin partly to locate the kidneys and to allow centering them is the field of the camera. Posterior views are taken with the subject lying face down. The pulse-height selector is then set to I^{131}, which effectively makes the camera insensitive to Hg^{203}, and 100-200 μc of I^{131} hippuran is administered intravenously. A series of pictures is taken with two minute exposures. In Fig. 4 A, B, and C, the Neohydrin picture is shown on the left and the hippuran pictures are shown at the right starting with the 0-2 minute exposure, then the 2-4 minute exposure, etc.

A normal subject is shown in Fig. 4A. The hippuran is rapidly taken up and cleared through both kidneys. In Fig. 4B, the Neohydrin picture reveals a large left kidney. The hippuran series shows delayed filling and holdup in the left kidney pelvis. In this example the hippuran pictures shown were taken at 0-2, 2-4, 4-6, 8-10, 14-16, 18-20, and 27-25 minutes. At a later operation, the left kidney was found to have cystic changes.

In Fig. 4 C are shown the kidneys of a 7-year old boy known to have leukemia. He developed hypertension, and routine radiographic studies showed both kidneys to be markedly enlarged. This change was believed to be secondary to leukemia-cell infiltration of the kidney tissue. The first stop-motion study showed practically no uptake of Neohydrin and hippuran by the kidneys. The right kidney was given 200r of X-radiation therapy over a period of several days. A second stop-motion study showed dramatic diminuation in the size of the right kidney, as demonstrated by the Neohydrin picture in Fig. 4 C, and marked improvement in the function of that kidney, as shown by the stop-motion hippuran excretion study. In this example, the hippuran series was taken at regular 2-minute intervals, except the last picture which was taken at 26-28 minutes.

Brain Tumor Studies

The use of Hg^{203} Neohydrin and the positron emitter Ga^{68} EDTA for localizing brain tumors with the scintillation camera has been described (2, 12, 13). With either agent, pictures are obtained with exposure times of 5-minutes.

Recently Tc^{99m} in the form of TcO_4^- (pertechnitate ion)(14) has been used with the scintillation camera. The 4000-hole lead-foil and balsa-wood multichannel collimator is employed. In Fig. 5 A and 5 B, the subject is a 9-year-old girl with a 3-week history of lethargy and motor incoordination. She was given

7 mc of Tc^{99m} and 45 minutes later frontal and lateral views were taken. Each was exposed for 4 minutes. Although a suspicious light area is seen at the center of the head in both views, the study was classified as equivocal because the transverse sinuses are located in this area. The patient was diagnosed as having an intrinsic pontine tumor, probably a glioma, from other findings. She was treated with X-ray radiation and obtained good recovery from her symptoms. This example is included to show the technical quality of pictures taken with this nuclide. It is one of the few that have been done with Tc^{99m}.

To show how quickly some tumors can be localized with this agent, Fig. 5C shows a 10-second exposure demonstrating a frontal lobe meningioma. The patient received 2 mc and 10,000 dots were recorded in the 10-second exposure.

Stop-Motion Scintiphotography of the Heart

In the course of examination of patients for brain tumors with TcO_4^- stop-motion pictures of the tracer compound going through the heart were also taken. The purpose was to demonstrate how much of the anatomy and function of the heart could be seen.

An example is shown in Fig. 6. The patient was supine and the camera viewed the anterior chest. Ten millicuries of Tc^{99m} was administered by rapid intravenous injection. The pictures were taken on 16 mm motion picture film at the rate of one frame per second. In the third frame the active bolus is located in the superior vena cava and the right atrium and ventricle. Early filling of the pulmonary artery is also seen. In the fifth frame, more activity is seen in the main pulmonary artery, and the right and left branches are beginning to fill. In the 14th frame the aortic arch, the ascending aorta, and the left atrium and ventricle are visible, as well as some residual activity in the pulmonary artery.

Thyroid Surveys

The special properties of pinhole and multichannel collimators can be used to advantage in thyroid examinations. The scintiphoto in Fig. 7 A, taken with the 1165-hole multichannel collimator, shows a 9-inch diameter area of the neck that includes the thyroid. This picture shows that the patient has no substernal extensions or hot nodules in the vicinity of the gland. In Fig. 7B is a scintiphoto of the same patient taken with the triple-aperture pinhole collimator that shows three different views of the gland (1). In the center is a frontal view showing a faint extension, visible as a short vertical line, of the patient's upper right lobe. On the right-hand side of the picture is an enlarged oblique view of the patient's right lobe showing the same extension as an oblique line to the upper right. This proves that the active abberant tissue is located anterior to the gland. On the left of

the picture is an enlarged oblique view of the patient's left lobe. The gland contained 7.6 μc of I^{131}, and the exposure times for the survey picture and the high-resolution closeup were 5 minutes each.

Bone Surveys with F^{18}

The 1.8-hour positron emitter F^{18} has been shown to concentrate in bone tumors and to reveal their presence in some cases before they are detectable on X-ray radiographs (15). The scintillation camera has also been used for this purpose (13).

After seeing scintiphotos of the deposition of F^{18} in small animals, shown later in this article, we became interested in other uses of this compound. Though F^{18} goes both to normal bone and soft tissues (16), and about 50% is normally excreted through the kidney, evidence indicates that F^{18} can be used as an indicator of bone blood flow (17).

To show the kind of pictures obtainable with this nuclide, the following examples are included. The deposition of fluoride ion in the skull of an adult is shown in Fig. 8 A. This left lateral view was taken about 3 hours after oral administration of 700 μc of F^{18} as NaF. Exposure time was three minutes. The relatively low uptake of fluoride in the lower jaw is believed due to the relatively poor circulation of blood to this part of the skeleton. The subject had all teeth intact.

The deposition of fluoride in the hand of the same subject at 4 hours is shown in Fig. 8 B. The picture shows the activity is not concentrated in the bones of the hand, but is in the soft tissues. The exposure time was 5 minutes and only 1.25 μc were present in the hand. The background dots are caused mostly by accidental coincidences from activity in the rest of the patient.

The deposition of F^{18} in a 73-year old man with Paget's disease is shown in Fig. 9. He received 280 μc intravenously, and a series of 10 fields were taken one to two hours later. Each field was exposed for 4 minutes. The pictures were punched out and mounted on a drawing of the skeleton for orientation. Because 4 of the areas were very intense, a less intense image of these areas is shown to the side. These were obtained from the previously described 6-lens oscilloscope camera used to record the pictures.

The distribution of fluoride in this patient was remarkable not only because of the localization in the bones involved in Paget's disease but the failure of F^{18} to appear in the uninvolved bones or the bladder. The patient

did not urinate between injection of F^{18} and taking the pictures. Apparently the F^{18} was taken up so rapidly by the diseased bone that the blood level fell extremely rapidly, and there was virtually no chance for uptake in normal bones or excretion via the kidneys.

Scintiphotography of Functioning Bone Marrow

The 8-hour positron emitter Fe^{52} and the scintillation camera can be used to map the functioning bone marrow in humans (9, 18). The radiation dose is not excessive (2.5 rad to the bone marrow for a 100 μc dose), and only about 1-2 hours are required to take the pictures. However, the nuclide must be made on a cyclotron and used promptly. The method of preparation has been described (19).

The distribution of marrow in a 19-year old girl is shown in Fig. 10. Sixty microcuries of Fe^{52} were given and the pictures were taken 16 hours later. Each field was exposed for 10 minutes. This girl was normal except for a mid-femural fracture 4 months previously which was healing normally. The scintiphotos show more marrow in the right femur distal to the fracture than the left. Pictures of the distribution of F^{18} in this same patient, showing high uptake at the site of the healing fracture, have been published elsewhere (17).

Studies of Tagged Agents in Animals

The behavior of radioactive fluoride ion when injected intravenously as NaF in a young 250 gm rat is shown in Fig. 11. Thirty microcuries of carrier-free F^{18} were administered and a series of 2-minute exposures were taken at 10, 45, and 90 minutes. The fluoride was distributed in all tissues at first, and then became concentrated in the bones, one kidney and the bladder. The kidney was sectioned later and was found to be hydronephrotic. It was first concluded that the fluoride deposited in the growing epyphysis of the bones, but later experiments with hypophysectorimized and normal rats, lead to the conclusion that fluoride deposits in the parts of bones where the circulation is greatest. It can therefore be used as an indicator of bone blood flow (17).

Uptake of F^{18} in Soft Tissue Calcifications

The uptake of F^{18} in the hind quarters of a young rabbit is shown in Fig. 12 A. The uptake is normal and symetrical except for a prominent spot at the lower right in the area of the left hind leg muscle. After killing the animal, the leg was cut off and skinned, and the picture in Fig. 12 B was taken. On dissection,

an area of abnormally pale muscle was seen that corresponded in position with the area of uptake. A roentgogram of an excised piece of the abnormal tissue revealed minute areas of increased density, presumably representing calcified degenerated muscle fibers. The calcification was extremely small, yet the accumulation of F^{18} was comparable to that of the adjacent bone. This finding suggests that F^{18} may be useful for demonstrating early calcification of diseased tissues.

Conclusion

The versatility, excellent resolution, and rapidity with which pictures can be obtained, as well as the relatively small doses of isotopes needed, makes the scintillation camera an ideal instrument for clinical and basic research, as well as for routine clinical diagnosis. It provides us with a more rapid means of finding materials that localize in specific places in the human body and illustrate specific functions. The foregoing examples have been selected to demonstrate the broad range of application of the scintillation camera.

Acknowledgments

The authors gratefully acknowledge the assistance of Mr. Philip Yost, Mrs. Jean Luce, and Mr. John Wood.

Bibliography

1. H. O. Anger, Nucleonics 21, 10, p. 56 (1963)
2. H. O. Anger, J. Nucl. Med. 5, 515 (1964); also in Lawrence Radiation Laboratory Report UCRL-11335 (1964).
3. H. O. Anger, in Donner Laboratory Semiannual Report UCRL-11184, p. 69 (1963).
4. J. R. Mallard, M. J. Myers, Phys. Med. Biol. 8, p. 165 (1963).
5. H. Yasukochi, Nippon Acta Radiologica 2, 246 (1964).
6. A. Gottschalk, H. O. Anger, "Renal Scintiphotography with the Gamma Ray Scintillation Camera and Hg^{203} Neohydrin" (in preparation).
7. W. G. Myers, J. Nucl. Med. 4, 182 (1963).
8. H. O. Anger, Lawrence Radiation Laboratory Report UCRL-11336 (1964).
9. H. O. Anger, D. C. Van Dyke, Science 144, 1587 (1964).
10. C. C. Harris, H. O. Eason, J. E. Francis, Jr., P. R. Bell, J. Nucl. Med. 1, No. 4, p. 280 (1960).
11. H. O. Anger, Lawrence Radiation Laboratory Report UCRL-11336 (1964).
12. H. O. Anger, A. Gottschalk, J. Nucl. Med. 4, p. 326 (1963).
13. A. Gottschalk, H. O. Anger, "Use of the Scintillation Camera to Reduce Scanning Time," (in preparation).
14. P. V. Harper, R. Beck. D. Charleston, K. A. Lathrop, Nucleonics 22, No. 1, p. 50 (1963).
15. M. Blau, W. Nagler, M. A. Bender, J. Nucl. Med. 3, 332 (1962).
16. P. Wallace-Durbin, J. Dent. Res. 33, 789 (1954).
17. D. Van Dyke, H. O. Anger, Y. Yano, C. Bozzini, "Bone Blood Flow shown with F^{18} and the Positron Camera," (submitted to Am. J. Physiol.)
18. D. Van Dyke, H. O. Anger, M. Pollycove, Blood 24, 356 (1964).
19. Y. Yano, H. O. Anger, "Production and Chemical Processing of Iron-52 for Medical Use" (submitted to Int. J. Appl. Rad. and Isotopes).

Figure Captions

Fig. 1. Scintillation camera with system for changing gamma-ray collimators rapidly. For positron emitters, collimators are pushed to the side as shown and collimation is achieved by coincidence techniques.

Figure 2. Pattern shown in window-indicating scope. (A) Photopeak line without PHS window, (B) Window too narrow, (C) Window below photopeak, (D) Window width and position correctly adjusted.

Figure 3. (A) Scintiphoto of normal-sized liver in adult. (B) Appearance when scintiphoto is viewed through diffusion filter.

Figure 4. Conventional and stop-motion kidney studies. Hg^{203}-Neohydrin pictures at left, exposure time 5 minutes. I^{131}-hippuran excretion series at right, exposure time 2 minutes per picture. (A) Normal, (B) Cystic left kidney, (C) Leukemic-cell infiltrated kidneys.

Figure 5. Brain Tumor studies taken with $Tc^{99m}O_4^-$. (A) Posterior view and (B) Right lateral view in subject with probable pontine glioma. Exposure time 4 minutes each. (C) Anterior view in patient with frontal lobe meningioma. Exposure time 10 seconds.

Figure 6. Stop-motion study of $Tc^{99m}O_4^-$ going through the heart after intravenous injection. Pictures taken at 1-second intervals.

Figure 7. (A) Scintiphoto of thyroid gland and surrounding area taken with multichannel collimator. (B) Scintiphoto of same thyroid taken with triple-aperture pinhole collimator.

Figure 8. (A) Left lateral view of adult head taken with F^{18}. (B) Hand of same subject. From the counts obtained, only 1.25 μC was present in the hand. Exposure times were 3 and 5 minutes.

Figure 9. Deposition of F^{18} in Pagets disease. Each circular area is a positron scintiphoto that was exposed for 4 minutes. The 4 areas connected by dotted lines are less-intense images obtained from 6-lens scope camera.

Figure 10. Distribution of erythropoietic marrow in 19-year old girl, normal except for femural fracture 4 months previously. Sixty μC of Fe^{52}, a positron emitter with an 8-hour half-life, was injected 16 hours before pictures were taken.

Figure 11. Deposition of F^{18} in a rat. Pictures were taken at 10, 45, and 90 minutes after injection.

Figure 12. (A) Anterior view of the distribution of F^{18} in pelvic area of a rabbit. The prominent spot at lower right is calcified muscle tissue. (B) View of left hind leg after rabbit was killed and leg amputated. The femur, tibia, foot, and calcified area of muscle are shown.

SCINTILLATION CAMERA WITH SYSTEM FOR CHANGING COLLIMATORS

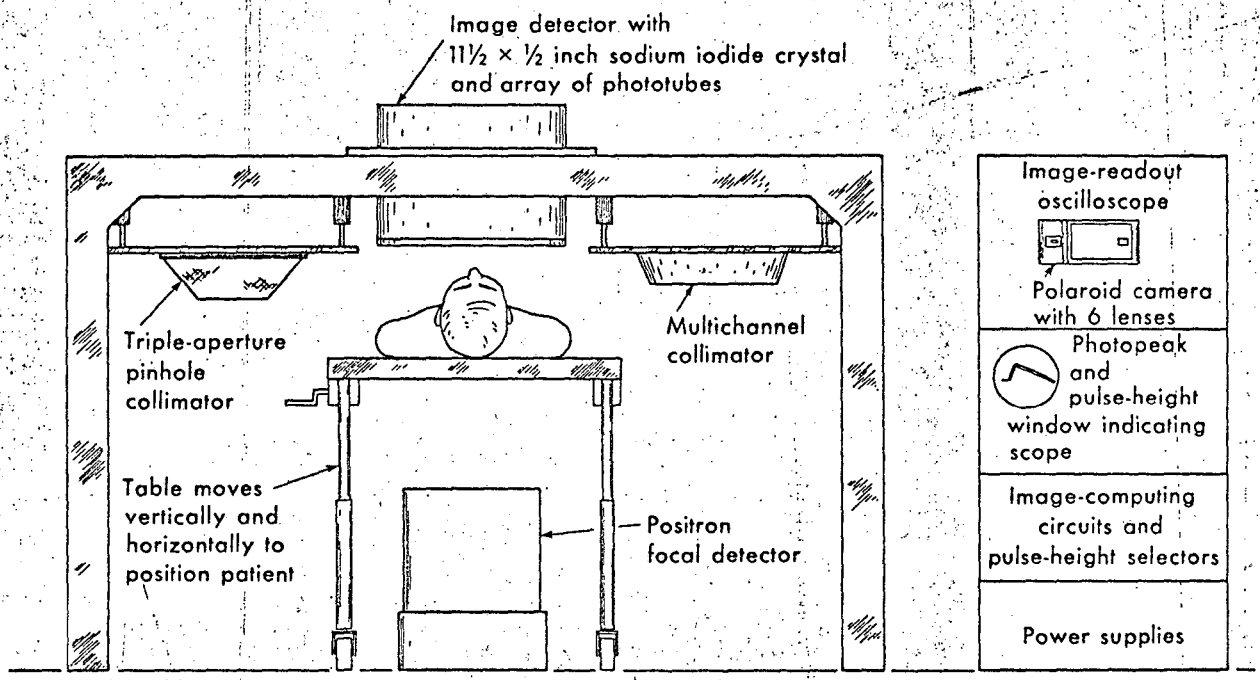

MUB-4355

Fig. 1.

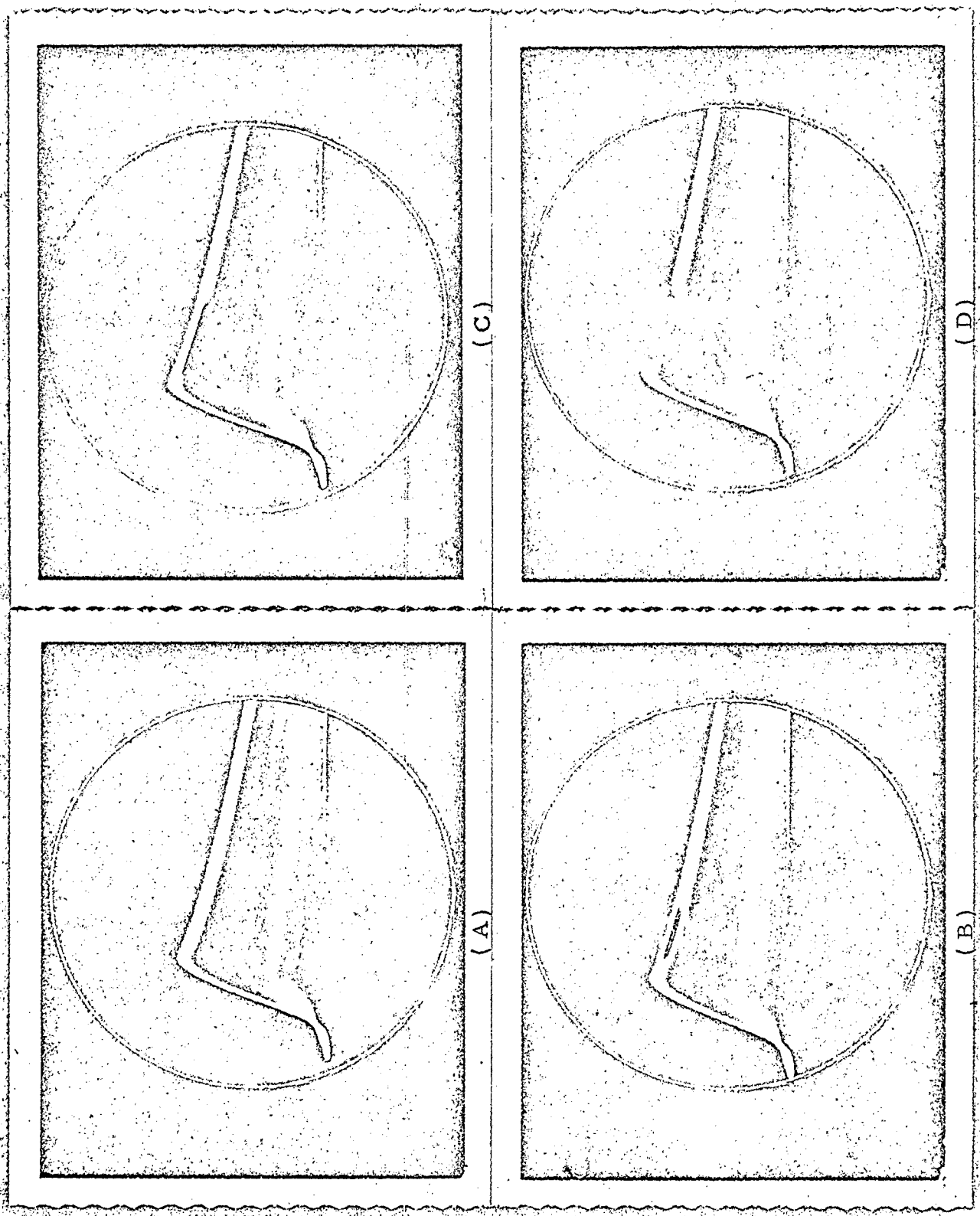

Fig. 2(A), (B), (C), and (D).

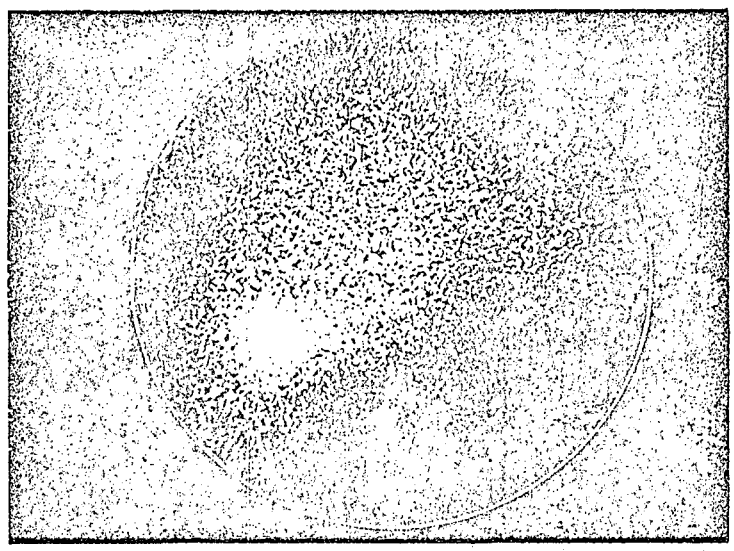

(A)



(B)

Fig. 3.

Fig. 3

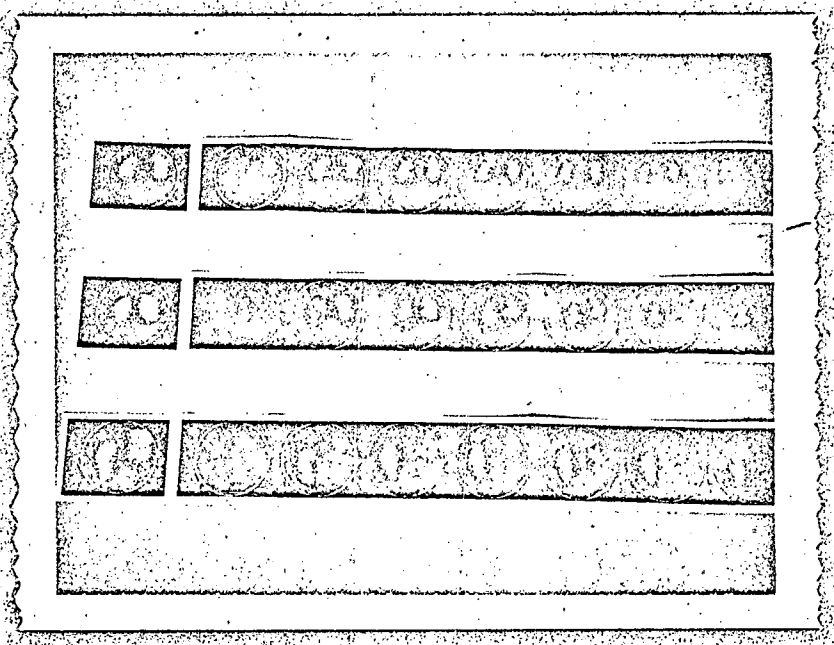

Fig. 4.

Fig 4



(A)



(B)



(C)

Fig. 5(A), (B), and (C).

Fig. 5

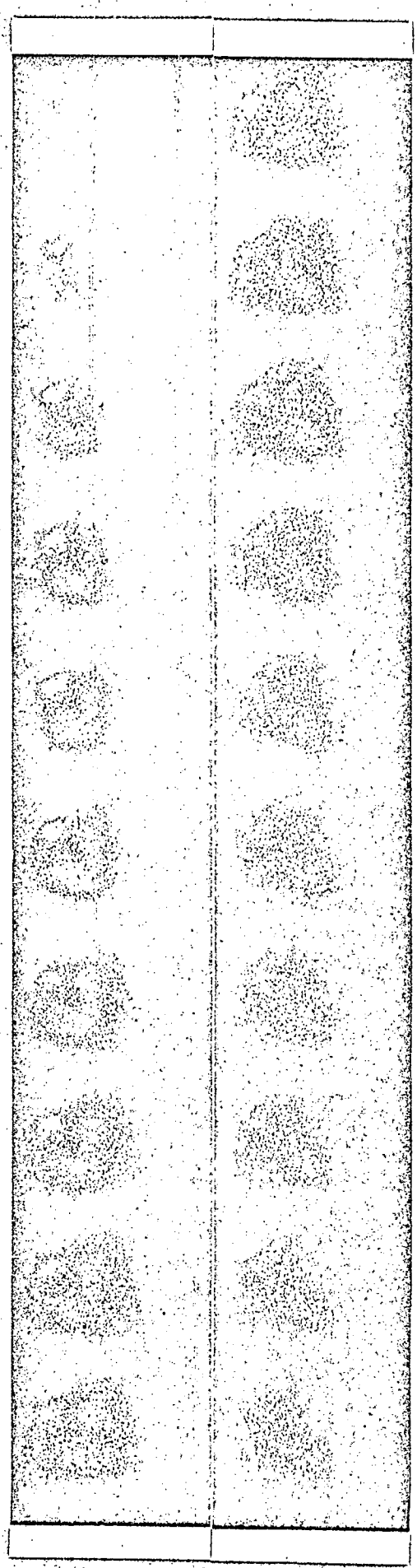

Fig. 6.

Fig. 6

(A)

(B)

Fig. 7(A), and (B).

Fig. 7

(A)

(B)

Fig. 8(A) and (B).

Fig 8

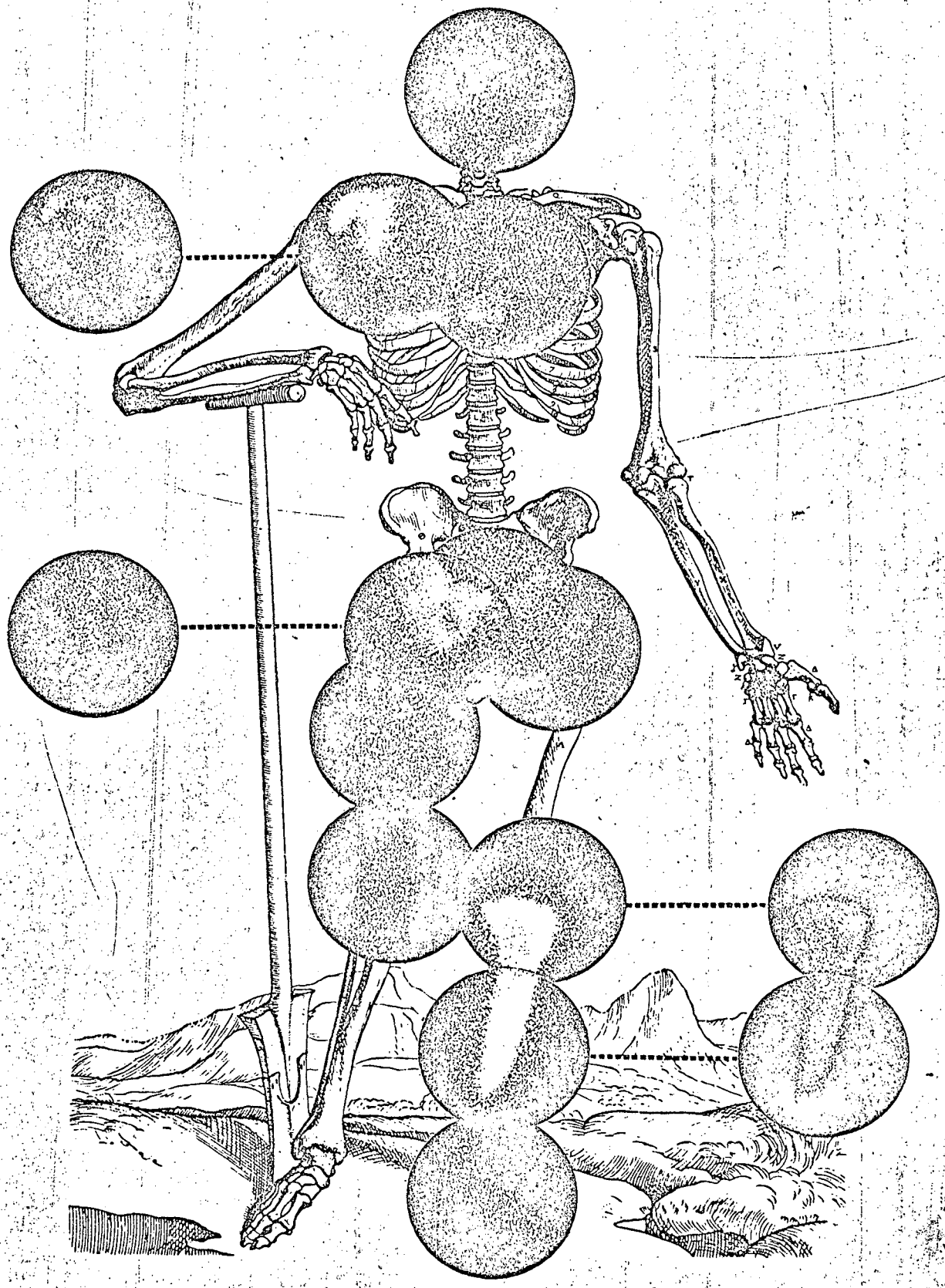

Mr. Schneider
F. Vogel's
Count = 1044

Fig. 9.

Fig. 9

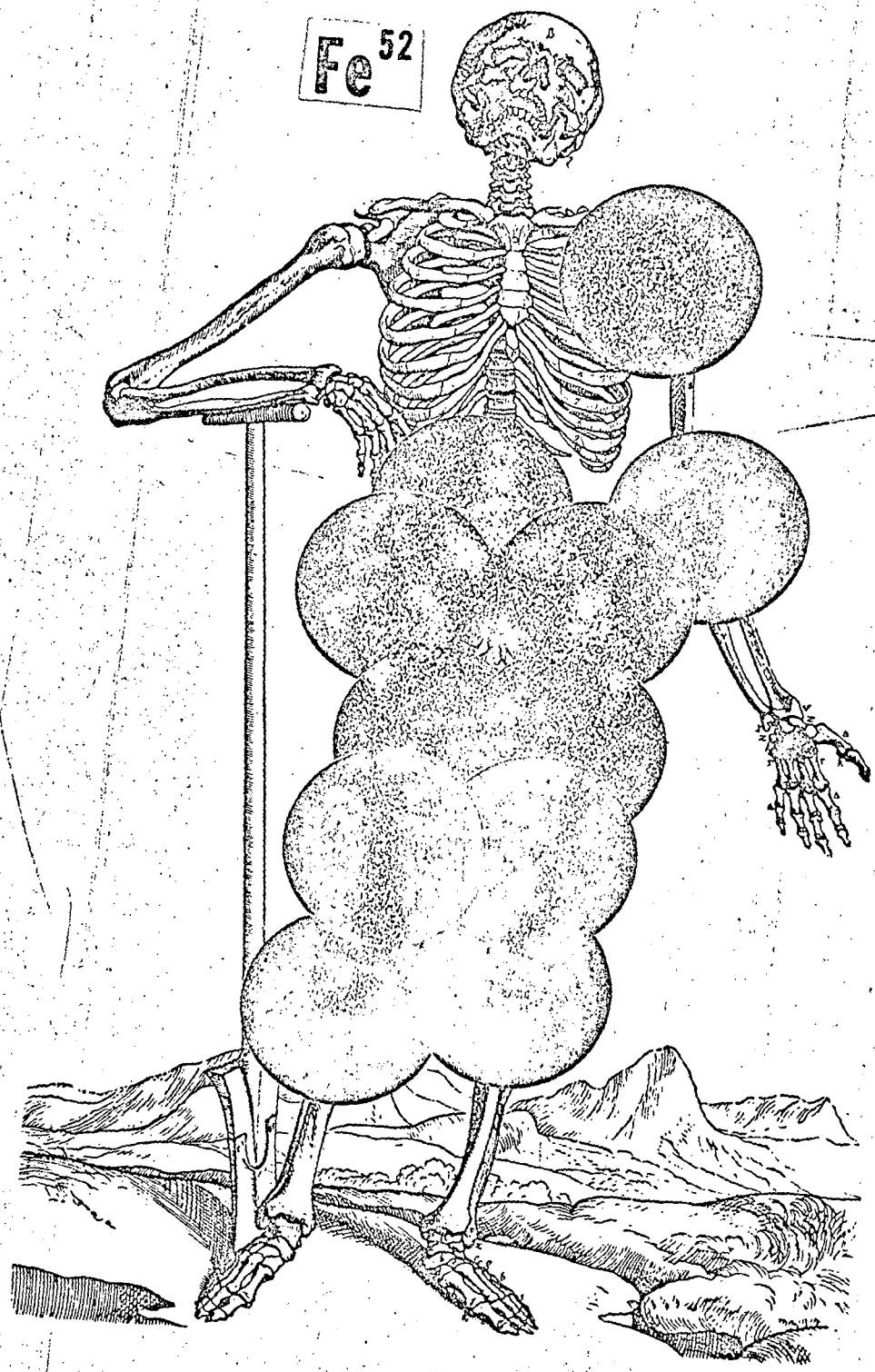

Fig. 10.

Fig. 10





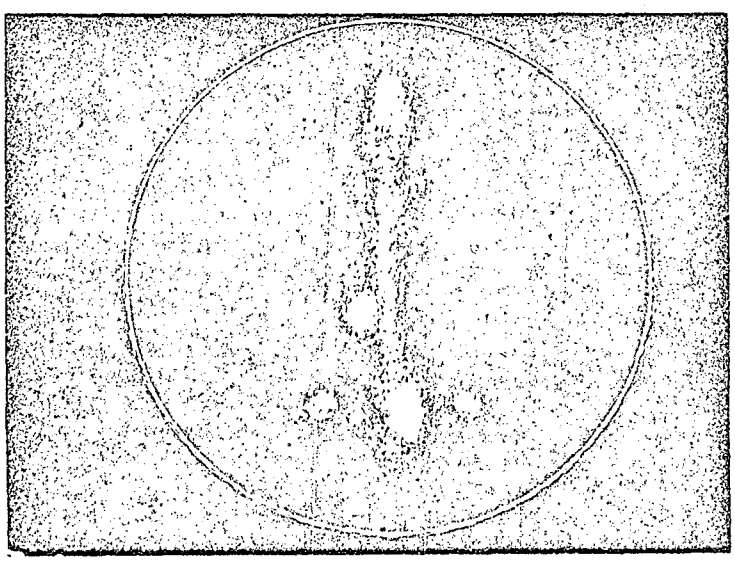

Fig. 11.

Fig 11



(A)

(B)

Fig. 12(A), and (B).

This report was prepared as an account of Government sponsored work. Neither the United States, nor the Commission, nor any person acting on behalf of the Commission:

A. Makes any warranty or representation, expressed or implied, with respect to the accuracy, completeness, or usefulness of the information contained in this report, or that the use of any information, apparatus, method, or process disclosed in this report may not infringe privately owned rights; or

B. Assumes any liabilities with respect to the use of, or for damages resulting from the use of any information, apparatus, method, or process disclosed in this report.

As used in the above, "person acting on behalf of the Commission" includes any employee or contractor of the Commission, or employee of such contractor, to the extent that such employee or contractor of the Commission, or employee of such contractor prepares, disseminates, or provides access to, any information pursuant to his employment or contract with the Commission, or his employment with such contractor.