UCRL-1613

UNCLASSIFIED

UNIVERSITY OF CALIFORNIA — BERKELEY

TWO-WEEK LOAN COPY

This is a Library Circulating Copy
which may be borrowed for two weeks.
For a personal retention copy, call
Tech. Info. Division, Ext. 5545

RADIATION LABORATORY

DISCLAIMER

This document was prepared as an account of work sponsored by the United States Government. While this document is believed to contain correct information, neither the United States Government nor any agency thereof, nor the Regents of the University of California, nor any of their employees, makes any warranty, express or implied, or assumes any legal responsibility for the accuracy, completeness, or usefulness of any information, apparatus, product, or process disclosed, or represents that its use would not infringe privately owned rights. Reference herein to any specific commercial product, process, or service by its trade name, trademark, manufacturer, or otherwise, does not necessarily constitute or imply its endorsement, recommendation, or favoring by the United States Government or any agency thereof, or the Regents of the University of California. The views and opinions of authors expressed herein do not necessarily state or reflect those of the United States Government or any agency thereof or the Regents of the University of California.

UCRL-1613
Unclassified-Health and Biology Distribution

UNCLASSIFIED

UNIVERSITY OF CALIFORNIA

Radiation Laboratory

Contract No. W-7405-eng-48

THE LOCALIZATION OF CERTAIN ALKALINE AND RARE EARTH ELEMENTS IN THE COSTOCHONDRAL JUNCTION OF THE RAT

C. W. Asling, J. G. Hamilton, Dorothy Axelrod-Heller
and Berniece Jue Louie

December 18, 1951

Berkeley, California

THE LOCALIZATION OF CERTAIN ALKALINE AND RARE EARTH ELEMENTS IN THE COSTOCHONDRAL JUNCTION OF THE RAT*

C. W. Asling, J. G. Hamilton, Dorothy Axelrod-Heller
and Berniece Jue Louie

From the Divisions of Anatomy, Experimental Medicine, Radiology, and
Medical Physics, the Crocker Laboratory, Radiation Laboratory, and the
Institutes of Experimental Biology and Medicine
University of California
Berkeley and San Francisco

December 18, 1951

The facts concerning the sites of localization of the alkaline earth, lanthanide, and actinide rare earth elements in skeletal tissues have been established in part by radioautographic and tracer investigations of the skeleton *in toto* and individual bones, notably the tibia and femur. The rat was the animal used for the series of investigations (Copp et al., '47; Hamilton, '47, '48, '49; Heller, '48; and Scott et al., '48).

This work indicated that the alkaline earths, notably strontium and barium, behaved in a manner which would suggest that their distribution in the skeleton was comparable to that of calcium. In the case of strontium this concept was quite adequately strengthened by the use of the radioautographic technique. None of the radioactive isotopes of barium had sufficiently long half lives to produce adequate radioautographs. However, from the tracer studies the evidence was strongly suggestive that this is a valid presumption. Furthermore, some limited radioautographic experiments with radium demonstrated that this radioactive element, the heaviest of the alkaline earth group, was deposited in bone in a manner similar to that of strontium (Axelrod et al., '48). In contrast to a tendency for the alkaline earth elements to distribute themselves in a pattern resembling that of calcium, it was observed that the two groups of rare

* This work was performed under Contract W 7405-eng-48-A-I at the University of California under the auspices of the United States Atomic Energy Commission.

earth elements demonstrated a preferential localization on most bone surfaces, notably in the endosteal and periosteal areas, and in some instances in the perivascular region of cortical bone.

To date it has not been justified to draw too firm conclusions concerning some of the details surrounding the factors pertinent to selective localization in bone. This, of course, includes the endosteal and periosteal layers and the uncalcified osteoid matrix. However, with respect to the last point Copp and his coworkers ('47) have shown in phosphorus-deficient animals that yttrium, cerium, and plutonium appear to be laid down in the uncalcified osteoid matrix. It is reasonable to predict that a comparable pattern should be observed with both the 4f and 5f series of rare earths; a description of these elements is presented later in this report. For example, it is of considerable interest to know whether the rare earth radioisotopes localize in newly formed bone layers or whether they are to be found instead in the osteogenic endosteal and periosteal tissue immediately adjacent. Ordinary contact radioautographs have not proved definitive in giving an answer to this question due to the fact that their resolution is too limited. Some of the most useful observations have arisen from artifacts as, for example, the demonstration of the deposition of plutonium in the periosteum which was shown very clearly in a section in which the osteogenic tissue was stripped free from the bone surface in sectioning. Stripping film and emulsion coating techniques offer much better resolution but there may be limitations in their use for thin brittle sections of undecalcified bone, as the areas of darkening in the emulsion may be suspected of originating in detached submicroscopic particles of tissue produced in the sectioning of the material. It should be pointed out that the decalcification of the bony tissue prior to sectioning must not be done for studies of this character. Obviously it is not feasible with any of the alkaline earth group which, of course, includes calcium. In the case of the two series of rare earth elements, translocation and

leaching by this treatment will lead to unreliable results.

Another approach to the problem was sought, apart from increased effort to improve actual technical procedures. It was felt that much might be gained by investigation of skeletal sites which offer special anatomical advantages. Specifically, it would appear desirable to use a site where normally there would exist periosteal tissue with osteogenic potential which yet did not lie immediately adjacent to bone. The organization of tissue at the costochondral junction appeared to offer the desired requirements. The anatomy of this region was described by Dawson and Spark ('28) and by Erdheim ('31) and only a brief review of the pertinent histological structure is necessary.

Figure 1 shows a histological section through the costochondral junction of an adult female rat. The specimen was not decalcified and following the application of the von Kossa technique for visualization of bone mineral the section was counter-stained by a modification of the Mallory technique. The upper half of the photomicrograph presents the cartilaginous segment of the rib and in the lower half may be seen the osseous portion. The junction line crosses transversely in the center. On either side is a continuous layer of fibrous connective tissue which, when overlying bone, is defined as periosteum.

Between the fibrous periosteum and the bone proper is a lighter staining cellular layer of osteogenic periosteum. This tissue continues beyond the junction line to end abruptly against cartilage, and is hereafter referred to as the "periosteal extension". (This has been marked in Figure 1 by a line extending from an X.) This small structure is of osteogenic potential and is elongated sufficiently so that it has no direct contact with bone mineral, as it is surrounded by either cartilage or fibrous tissue. The periosteal extension has a histogenic equivalent in the cartilaginous segment - the thin surface layer of undifferentiated cartilage cells just adjacent to the fibrous perichondrium. It is this periosteal-perichondrial transition zone which is the region of special interest. An additional area of

significance is the cartilage segment proper. There may be seen an outer layer of non-calcified hyaline cartilage and beneath it a core of calcified cartilage. Within this calcified core there is frequently a slender strand of non-calcified cartilage. This strand is so small that it can only be seen with very favorable planes in the section procedure. The cartilage structure of the costochondral junction is devoid of vessels and any substance found to be localized in or near the calcified region had to attain this position by permeation of the dense cartilage matrix.

Accordingly, radioactive isotopes of the alkaline earths, calcium and strontium, the lanthanide rare earth, promethium (element 61), and the actinide rare earths, plutonium (element 94) and americium (element 95), were prepared for injection into adult rats with a body weight of from 200 to 250 grams.

The lanthanide group of elements belongs to Group III of the Periodic Table and extends from cerium to lutecium (elements 58 to 71). These elements, a number of which are formed from nuclear fission, bear a remarkable chemical and metabolic similarity to one another. Chemically they are primarily trivalent and form highly insoluble hydroxides, phosphates, and carbonates. The actinide series of elements extends from thorium to californium (elements 90 to 98). Their chemical properties in certain circumstances resemble those of the lanthanide group, although there are somewhat wider variations in their valence states and chemical properties.

Dosage and route of injection varied depending upon the radioelement employed and its known chemical and metabolic properties, which are specified under the headings of the radioelements described below. The main factor in the determination of the dosage was the requirement of obtaining sufficient degree of uptake to make it possible to secure satisfactory radioautographs under the conditions of the experiment. The dosages employed were considered to be below

a level which would induce radiation injury for the time intervals employed. It should be pointed out that a quantitative comparison from one radioautograph to another cannot be made, but rather these data are restricted to a qualitative evaluation for each radioelement.

The rats used in these experiments were sacrificed at two post-injection intervals, namely one and twenty-four hours. The seventh to ninth costochondral junctions were removed in one piece and fixed in alcohol. Undecalcified histologic sections and radioautographs were prepared following the techniques of Axelrod-Heller ('47 and '51). Following the removal of the film and its development, the sections were stained by the von Kossa technique for visualization of bone mineral and counter-stained with hematoxylin and eosin.

RESULTS

Almost invariably, the radioautographs at the two post-injection periods were similar and therefore only the earlier interval, one hour, is presented for each radioelement studied.

Calcium: Figures 2 and 3 are the histologic section and radioautograph, respectively, of the costochondral junction of a rat, one hour after intraperitoneal injection of 6 microcuries of Ca^{45}. This preparation of Ca^{45} contained approximately 10 micrograms of stable calcium and therefore cannot be more precisely considered as being carrier-free. The term "carrier-free" signifies that the radioelement was not diluted with detectable quantities of stable non-radioactive isotopes of the same element. The distribution of the radio-calcium corresponds to the mineralized region of the bone and cartilage. The cortical bone of the rib showed a somewhat heavier localization on the periosteal and endosteal surfaces than within the mineralized bone structure proper. The spongiosa demonstrated a quite marked localization which is understandable in view of the presumed greater mineral turnover in this region as contrasted to the dense cortical portion of the mineralized bone. No radioautographic evidence was to be seen that radio-calcium was deposited beyond the costochondral junction, indicating no perichondrial

deposition. The calcified cartilage shows a deposition comparable in intensity to that of the cortical bone.

Specimens from animals sacrificed twenty-four hours after the administration of the radio-calcium were comparable to the results shown here after the one hour interval, with the exception of a more uniform deposition of this radioelement through the cortical bone.

Strontium: The radioisotope employed for these studies was carrier-free Sr^{90} produced by nuclear fission. This radioelement has a quite long half life, but has a radioactive daughter, yttrium, with a half life of sixty hours. To avoid any abberations in the radioautographic studies the material was purified before injection to free it from all Y^{90} present. In view of the fact that the half life of Y^{90} is sixty hours, an almost undetectable quantity of Y^{90} would grow from Sr^{90} after an interval of one hour. At the end of twenty-four hours there would be less than 25 per cent of the total activity arising from Y^{90}. It must be kept in mind that when the animals are sacrificed the Y^{90} could have no appreciable effect in distorting the experimental results and the specimens were treated in such a manner throughout the procedures of fixation, embedding, sectioning, and finally the preparation of the radioautographs, that it could not be expected that there would be any translocation of the Y^{90} from the regions where its parent Sr^{90} was deposited.

Figures 4 and 5 demonstrate that one hour after the intraperitoneal injection of 10 microcuries of carrier-free Sr^{90} the localization of this alkaline earth behaves in a manner that corresponds closely to the radioautographic patterns obtained with radio-calcium. It is noteworthy that in experiments employing shorter time intervals between the administration of the radioelement and the sacrifice of the animals, it is readily demonstrated that the pattern of deposition was very similar. These time intervals extended down to periods as short as five minutes. However, it must be taken into consideration that in these very short term studies the radio-strontium was given by the intravenous route. The only

significant variation encountered with the short time interval was that the deposition was limited primarily to the periosteal and endosteal regions of the bone and the surface of the calcified portion of the costal cartilage.

The twenty-four hour study with radio-strontium was almost indistinguishable from the corresponding time interval for radio-calcium. The radio-strontium was quite diffusely distributed throughout the cortical bone. It is of interest to note that at this longer time interval there was no appreciable variation in the radioautographic patterns which indicates that even though some radio-yttrium had been present, it apparently had no detectable effect insofar as provoking changes in the radio-strontium radioautograph was concerned.

A careful comparison of the radioautographs of these two radioelements reveals that the pictures obtained from radio-calcium had slightly better definition. This effect arose from the fact that the beta rays from both radio-strontium and its radioactive daughter, yttrium, are much more energetic than those from radio-calcium. It is a common experience in radioautography to find that the more energetic the beta particles are, the less is the resolution obtained from the radioautographic image.

Promethium: Due to the fact that promethium (element 61), like other members of the lanthanide rare earths, is not readily absorbed following parenteral injection, a much larger dose, which was 500 microcuries, had to be employed to secure sufficient uptake in the costochondral structure to assure adequate radioautographs. To accelerate its absorption it was injected intraperitoneally, complexed with sodium citrate. Intravenous injection was avoided due to the tendency of this group of radioelements, even in the carrier-free state, to exhibit pronounced colloidal-like effects, and such effects might give rise to a distorted radioautographic pattern since small colloid particles are known to be trapped in the reticulo-endothelial system of the bone marrow. Figures 6 and 7 demonstrate the localization of this radioelement at the one hour post-injection interval. The localization is primarily on the periosteal and endosteal surfaces and it will

be noted at the region where the bone was cut tangentially, there was a spotty distribution throughout the cortex. This type of distribution has been observed in the cortex of the femur (Hamilton, '47, '48, and '49). The heavy solid darkening noted in the region of the spongiosa is due to the fact that the resolution of the radioautograph was inadequate to show that promethium is not accumulated within the mineralized portion of the spongiosa.

The striking observation to be made from Figures 6 and 7 is the fact that there is marked deposition of promethium which corresponds exactly to the periosteal extension. Both this extension of periosteal tissue and the radioautographic evidence for the accumulation of promethium in this structure are indicated by the arrows. Since no bone salts or bone matrix are demonstrable in the neighborhood of this tissue, it would appear reasonable to make the assumption that in this area the osteogenic cells of the periosteum have accumulated and retained promethium. A somewhat fainter image, extending from this tissue along the perichondrium, again showing no relationship to bony tissue, also suggests the capacity of these less differentiated cells to accumulate and retain promethium. There is also deposition of promethium in the rib cartilage at the transition zone between calcified and non-calcified cartilage. No appreciable penetration of promethium into the calcified core was observed.

The specimens secured from animals sacrificed twenty-four hours following the administration of 200 microcuries of promethium by intraperitoneal injection demonstrated a deposition pattern very similar to that just described. No penetration into the calcified core of the cartilage was observed, though marked darkening took place at the border between the calcified core and the cartilage proper. This effect presumably arose from two factors: first, there was a greater accumulation of promethium due to the longer interval, even though the amount of promethium administered was less and, second, the radioautograph was somewhat over-exposed.

Plutonium: Pu^{239} was administered to the experimental animals by intraperitoneal injection. Each animal received 12 microcuries of plutonyl nitrate,

complexed with the citrate ion to facilitate absorption. The animals, as in the preceding groups, were sacrificed one and twenty-four hours after injection. From the histological preparation and the radioautograph, Figures 8 and 9, for the one hour period, it is apparent that plutonium is quite sharply restricted to periosteal and endosteal surfaces and, unlike promethium, no spotty deposition in the cortex of the rib was noted. The presence of plutonium is demonstrable in the periosteal extension, as may be seen from the arrows. The effect seems to be less than that noted with promethium. However, the important point is that plutonium, like promethium, is taken up by the cells of this structure.

The radioautographs from the animals sacrificed at twenty-four hours were quite similar to the data secured from the one hour group. Deposition of plutonium in the cartilaginous portion of the rib appears to be limited to the interface between non-calcified and calcified cartilage.

Americium: One hundred and fifty-six microcuries of Am^{241} complexed with citrate ion were administered by intramuscular injection and the animals sacrificed at one and twenty-four hours after the injection time in order to secure the costochondral rib specimens. It may be seen in Figures 10 and 11 that the deposition of this radioelement was confined to the periosteum and endosteum of the bone, and as indicated earlier, the resolution was not sufficient to demonstrate this effect in the mineralized portion of the spongiosa. The americium radioautographs were quite light due to a low degree of absorption at the time intervals employed. A comparison with the promethium experiments, Figures 6 and 7, indicates considerable similarity and it is evident that americium, like promethium, is deposited in the region of the perichondrium. The apparent absence in both the one and twenty-four hour intervals of americium in the periosteal extension may have resulted from an unfavorable section to demonstrate this phenomenon. Earlier work in which the metabolic properties of promethium and americium have been studied in detail, including radioautographs of the undecalcified femur, indicate that these two radioelements are almost indistinguishable

in this regard (Hamilton, '47, '48, and '49). In view of these facts, it would appear likely that the apparent absence of the deposition of the periosteal extension is not a basic difference in the distribution pattern of these two radioelements at this particular anatomical site. In the preparation presented here no americium was noted to be present within the cortical bone of the rib although this spotty type of deposition has been observed unequivocally in the cortical bone from the femur of a rat. However, the thin cortex of the rib is relaitvely avascular and thus frequently offers poor opportunity to demonstrate these perivascular depositions.

The preparation secured from animals sacrificed at the twenty-four hour interval did show the typical spotty deposition within the compact bone. However, no definite evidence of accumulation of americium was noted in the region where the periosteal extension should be found.

The reason for evidence of the perivascular distribution of americium in the cortical bone arose from the fact that the section was secured in a favorable tangential plane.

DISCUSSION

There are several possible sites for the localization of bone-seeking elements. Among these are the following: (1) Chemical incorporation into the apatite or bone mineral, (2) physical association, as for example adsorption, of the bone mineral, (3) deposition in the organic matrix of bone independent of the existing bone mineral, and (4) deposition in the bone-forming cells. The present experiment does not demonstrate the precise site of bone localization in all areas of each of the alkaline and rare earths studied, but does allow some selection to be made from among these possibilities listed above.

As has been previously observed, calcium and strontium were invariably deposited in a pattern identical to that of the pre-existing mineral, whether that of the bone proper or of the core of calcified cartilage of the rib. The great rapidity with which strontium appeared in the mineral of this latter site is suggestive evidence for physical association as well as chemical incorporation

with the bone mineral, as is presumably true in the case of calcium.

The three rare earth metals were not found to be dispersed throughout the pre-existing bone mineral and calcified cartilage in a manner resembling that of the alkaline earths. Promethium and plutonium could be demonstrated in the periosteal extension in a region where neighboring bone mineral could virtually be excluded as a possible site of localization. In the case of americium, the presence of this radioelement in the periosteal extension was not seen. Promethium and americium appeared to be deposited in the region of the perichondrium and in the case of plutonium this deposition could be seen but was very faint. This type of perichondrium localization was not observed for the alkaline earths. The results are rather convincing with respect to the deposition of promethium and plutonium on the surface of the calcified cartilage. This suggests that they may have borne some physical association with the mineral. In the case of americium, the results are a little more ambiguous and there may have been some association with the mineralized portion of the cartilage.

SUMMARY

Radioactive isotopes of calcium, strontium, promethium, plutonium, and americium possessing a high degree of specific activity were administered by parenteral injection to adult rats. One and twenty-four hours following administration of these radioelements, animals were sacrificed and radioautographs prepared from histologic sections through the costochondral junctions. In this report only the one hour data are given in the form of photomicrographs of the costochondral junction and its corresponding radioautograph.

All five radioelements have apparently localized, in varying degrees, in both the bony and the cartilaginous segment of the rib at the end of the one hour interval, though in the case of americium there is a question of its localization in the mineralized cartilaginous segment of the rib. Promethium, plutonium, and possibly americium, were present in the periosteal extension of the rib cartilage.

LITERATURE CITED

Axelrod, D. J. - An Improved Method for Cutting Undecalcified Bone Sections and Its Application to Radioautography. Anat. Rec. 98:19-24 (1947).

Dawson, A. B., and Charles Spark - The Fibrous Transformation and Architecture of the Costal Cartilage of the Albino Rat. Am. J. Anat., 42: 109-137 (1928).

Copp, D. H., D. J. Axelrod, and J. G. Hamilton - The Deposition of Radioactive Metals in Bone as a Potential Health Hazard. Am. J. Roent. and Rad. Therap., 58: 10-16 (1947).

Erdheim, J. - Die Lebensvorgänge im normalen Knorpel und seine Wucherung bie Akromegalie. J. Fisher, Berlin (1931).

Hamilton, J. G. - The Metabolism of the Fission Products and the Heaviest Elements. Radiology, 49: 325-343 (1947).

Hamilton, J. G. - The Metabolic Properties of the Fission Products and Actinide Elements. Rev. of Mod. Phys., 20: 718-728 (1948).

Hamilton, J. G. - The Metabolism of the Radioactive Elements Created by Nuclear Fission. New Engl. J. of Med., 240: 863-870 (1949).

Heller, Minnie - Histopathology of Irradiation. Ed. by William Bloom. McGraw-Hill, New York. Chapter V, Bone. (1948).

Scott, J. G., D. H. Copp, D. J. Axelrod, and J. G. Hamilton - The Metabolism of Americium in the Rat. J. Biol. Chem., 175: 691-703 (1948).

Scott, K. G., D. J. Axelrod, and J. G. Hamilton - The Metabolism of Curium in the Rat. J. Biol. Chem., 177: 325-335 (1948).

LEGENDS FOR ILLUSTRATIONS

Figure 1. Costochondral junction of normal adult female rat, in undecalcified histologic section stained by von Kossa silver technique for calcium, followed by modified Mallory stain. Cartilaginous segment toward top. "X" indicates extension of the osteogenic layer of periosteum into the cartilaginous segment. Magn. x 83 .

Figures 2 - 11. Histologic sections and radioautographs of costochondral junction of normal adult female rats. Sections cut at 8 - 10 μ, stained by von Kossa silver technique for calcium, counter-stained with H E. Magn. x 19.

Figures 2 and 3. Histologic section and radioautograph of costochondral junction of normal adult female rat. Rib removed one hour after injection of Ca^{45}. Section stained by von Kossa silver technique for calcium, counter-stained with H E. Magn. x 19.

Figures 4 and 5. Costochondral junction one hour after Sr^{90}. Technique as in Figures 2 - 3.

Figures 6 and 7. Costochondral junction one hour after Pm^{147}. Arrows indicate periosteal extension. Technique as in Figures 2 - 3.

Figures 8 and 9. Costochondral junction one hour after Pu^{239}. Arrows indicate periosteal extension. Technique as in Figures 2 - 3.

Figures 10 and 11. Costochondral junction one hour after Am^{241}. Technique as in Figures 2 - 3.

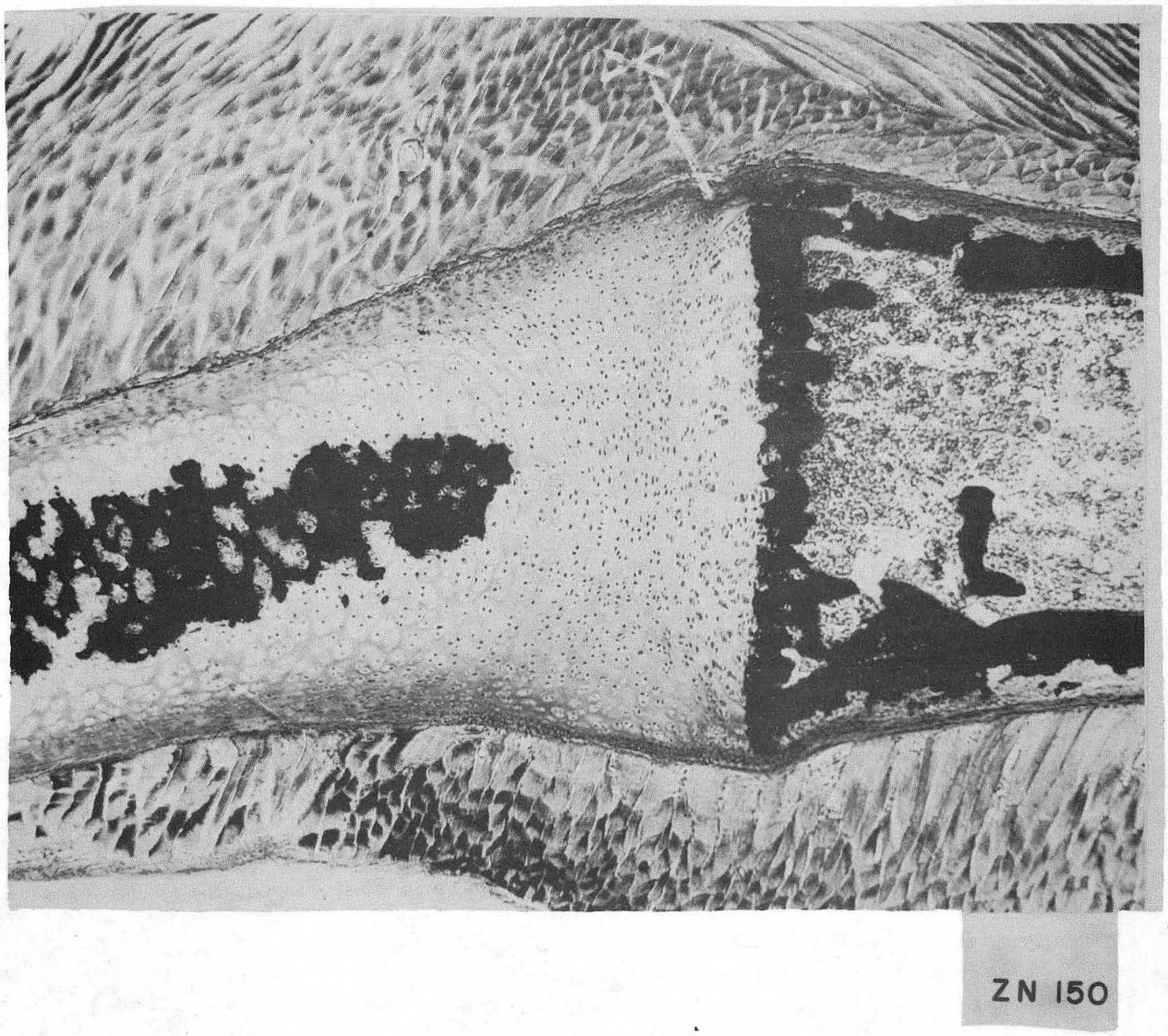

Fig. 1

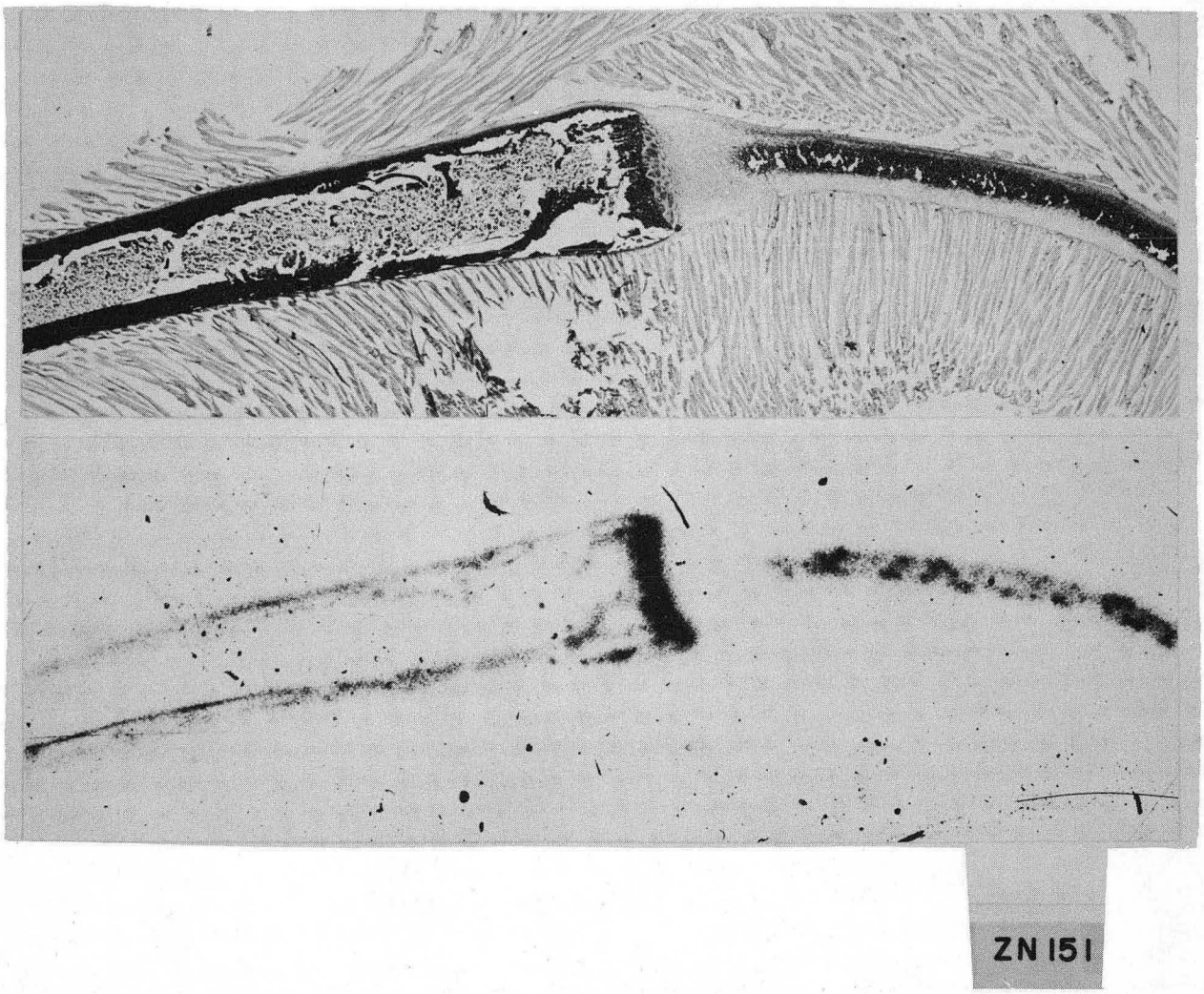

Fig. 2
Fig. 3

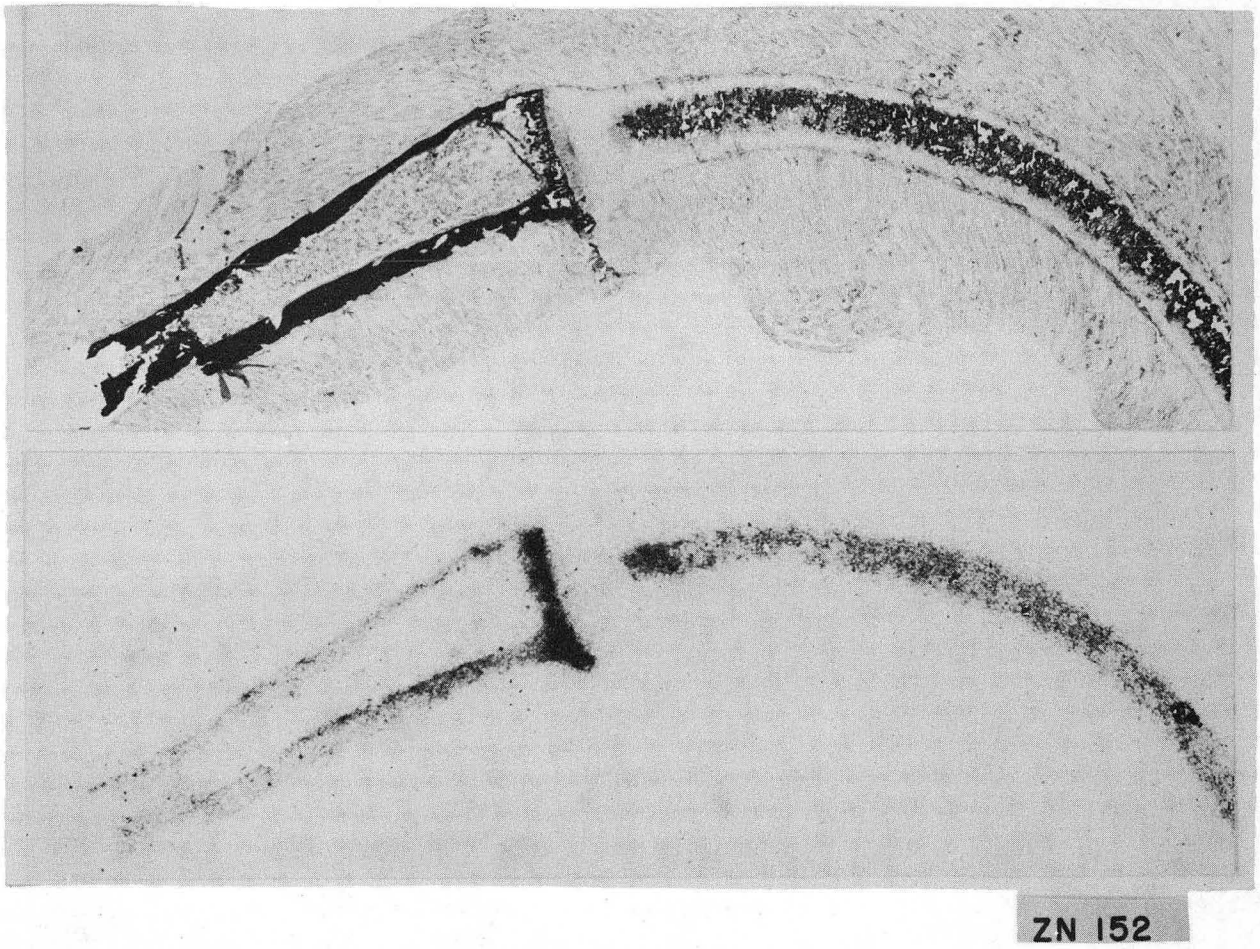

Fig. 4
Fig. 5

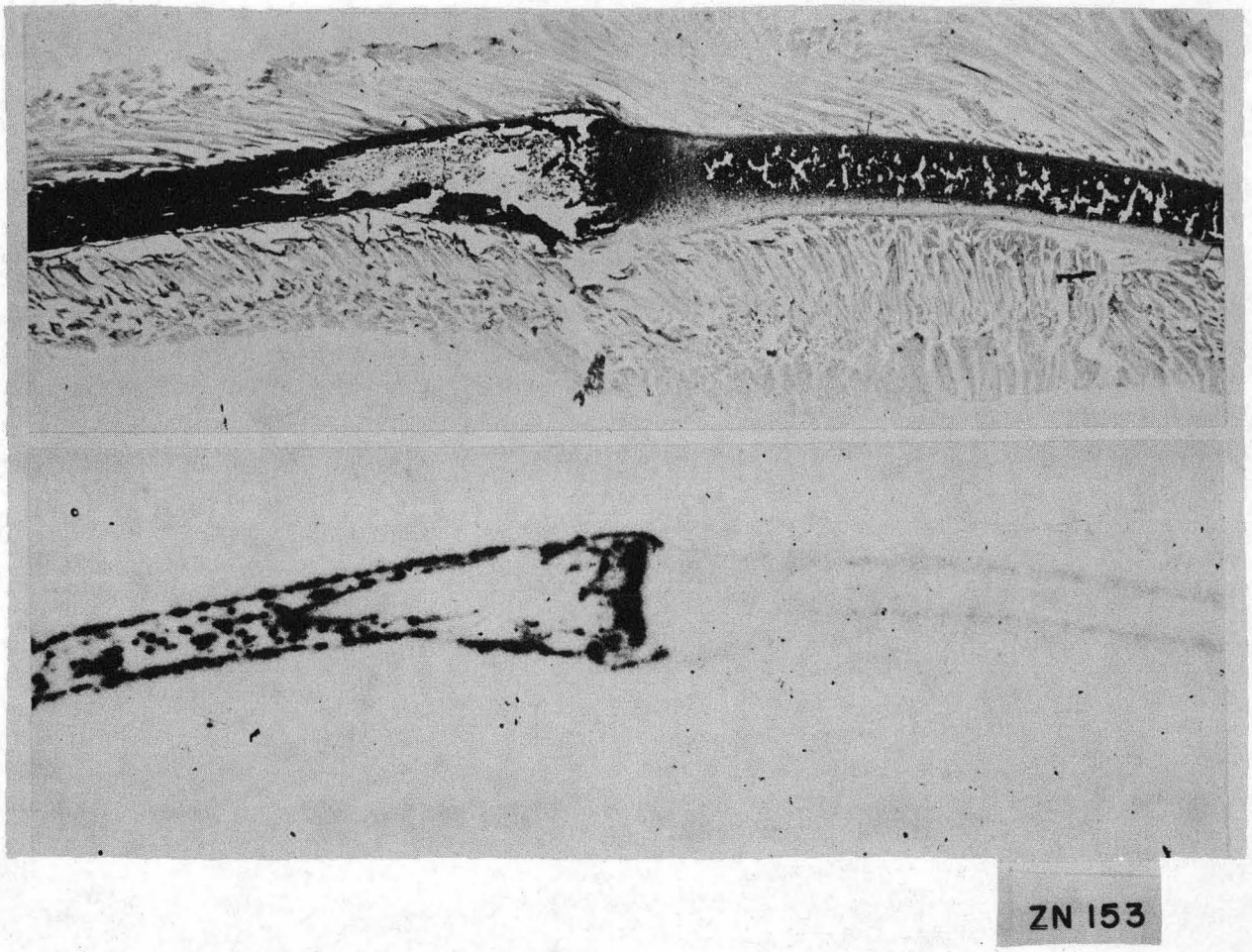

Fig. 6
Fig. 7

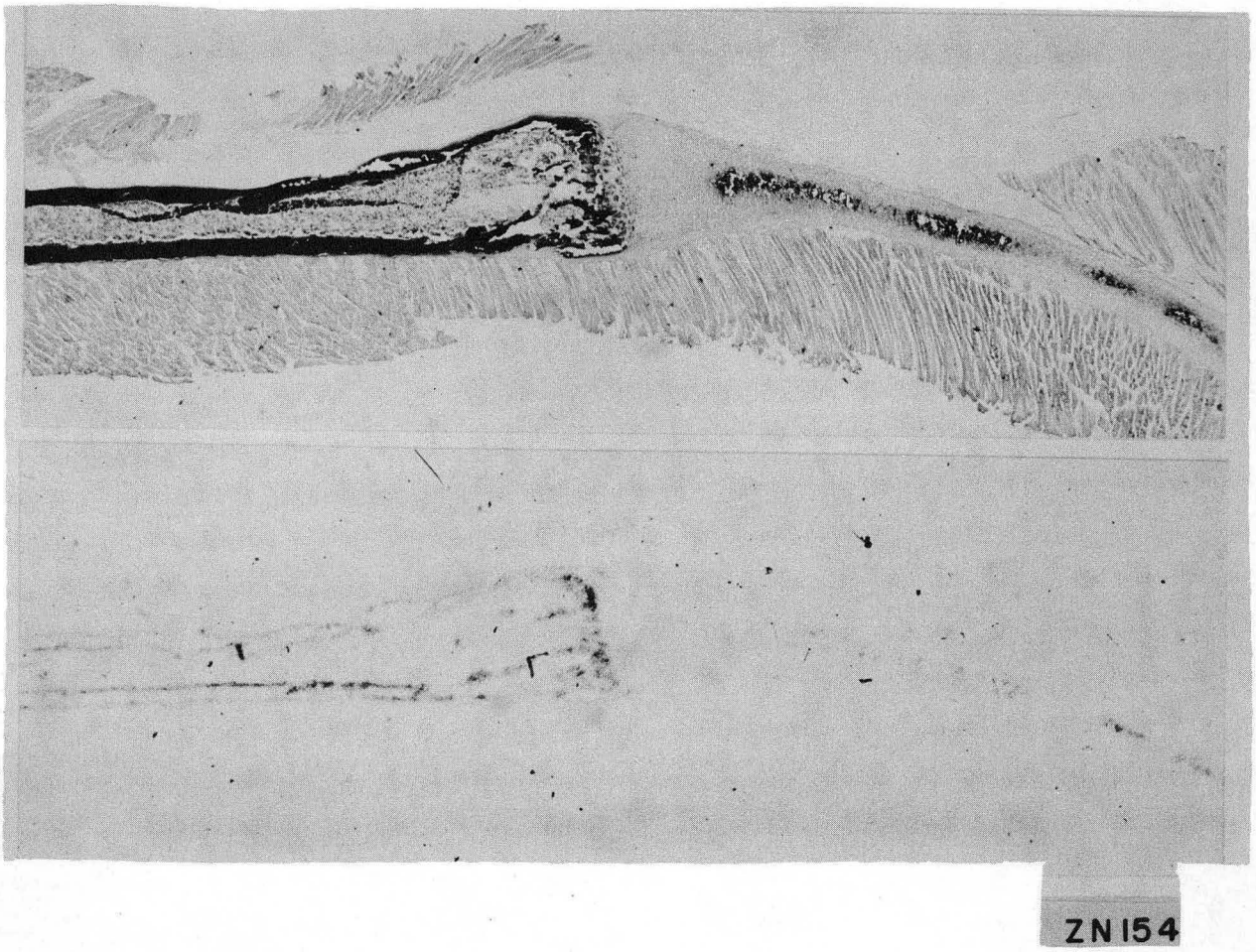

Fig. 8
Fig. 9

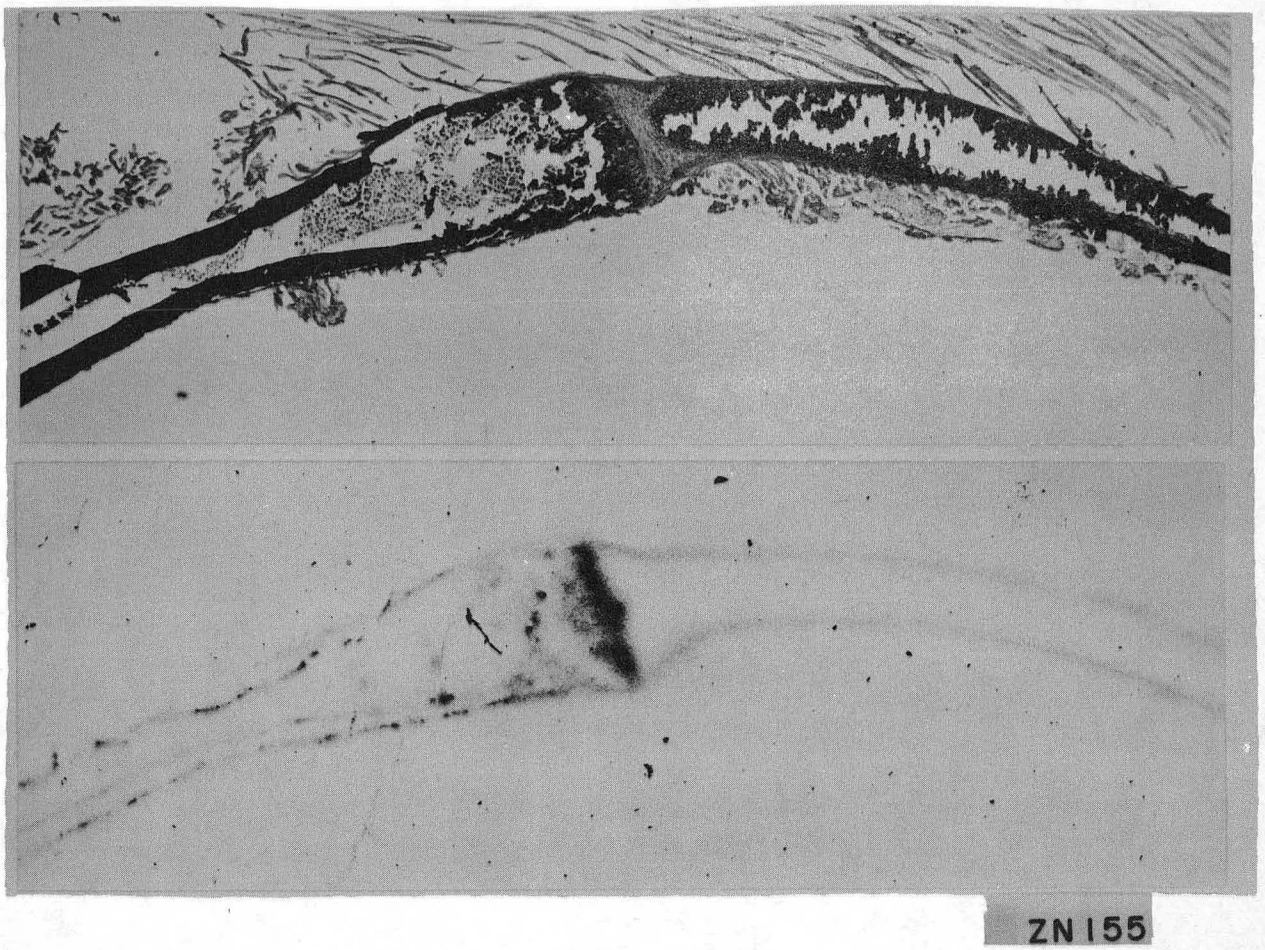

Fig. 10
Fig. 11