UCRL-8995

Cy.2

UNIVERSITY OF CALIFORNIA

Ernest O. Lawrence Radiation Laboratory

TWO-WEEK LOAN COPY

This is a Library Circulating Copy which may be borrowed for two weeks. For a personal retention copy, call Tech. Info. Division, Ext. 5545

BERKELEY, CALIFORNIA

DISCLAIMER

This document was prepared as an account of work sponsored by the United States Government. While this document is believed to contain correct information, neither the United States Government nor any agency thereof, nor the Regents of the University of California, nor any of their employees, makes any warranty, express or implied, or assumes any legal responsibility for the accuracy, completeness, or usefulness of any information, apparatus, product, or process disclosed, or represents that its use would not infringe privately owned rights. Reference herein to any specific commercial product, process, or service by its trade name, trademark, manufacturer, or otherwise, does not necessarily constitute or imply its endorsement, recommendation, or favoring by the United States Government or any agency thereof, or the Regents of the University of California. The views and opinions of authors expressed herein do not necessarily state or reflect those of the United States Government or any agency thereof or the Regents of the University of California.

UCRL-8995

UNIVERSITY OF CALIFORNIA

Lawrence Radiation Laboratory
Berkeley, California

Contract No. W-7405-eng-48

CORRELATION OF HISTOCHEMICAL, AUTORADIOGRAPHIC, AND MICRORADIOGRAPHIC DEMONSTRATIONS OF TISSUE CALCIFICATION

Muriel E. Johnston, Patricia W. Durbin and C. Willet Asling

December 1959

In the course of radioisotopic studies on the site of the earliest deposition of bone-seeking rare earth elements, it became necessary to establish with precision the reliance which could be placed on histochemical procedures for the visualization of bone mineral. In particular, the adequacy of the von Kossa silver nitrate method for detecting new and sparse deposits of calcium in the developing skeleton required investigation. Cerium had been reported as localizing in fetal sites (vertebral centra, hyoid bone) in advance of areas showing a positive von Kossa reaction, suggesting a primary association with calcifiable rather than calcified structures (Asling et al., 1957).

A comparative study of a number of procedures recommended for the histochemical demonstration of calcification was reported by McGee-Russell (1958). The critical nature of that study made it possible to exclude a number of unsuitable tests in the present investigation. Two procedures not employed by McGee-Russell have been included, namely, calcium-45 autoradiography and soft x-ray microradiography. The former made it possible to identify sparse and new-forming calcium deposits by an *in vivo* technique. The latter provided a factor common to all sections studied. In studies on staining procedures, the necessity for basing comparisons on adjacent sections is restrictive, since even with thin sections anatomical details are not identical. By preparing microradiographs of each section before applying the histochemical tests, each staining procedure may be evaluated against a constant physical test for tissue calcification -- x-ray absorption. The histochemical tests used included the von Kossa and the alizarin-red S stains. In addition, an apparently little-known ferrocyanide reaction, differing markedly from that found inadequate by McGee-Russell, was used. As will be discussed, it appears that these three staining procedures may be regarded as representative of distinct groups of reactions for visualization of calcification in tissues.

EXPERIMENTAL

The test sites employed were the developing bones of the rat fetus (Long-Evans strain). In particular, sagittal sections through the 18- or 19-day rat fetus provided a demonstration of the entire succession of events in endochondral osteogenesis, due to the progressive appearance of ossification centers in the vertebral centra. As shown by Wright et al. (1958), ossification starts in the lower thoracic centra on the 18th day of gestation[2] and over the next few days extends rapidly in the rostral, and somewhat more slowly in the caudal direction. A mid-sagittal section, to which a von Kossa and a periodic acid-Schiff stain have been applied, is seen in Fig. 1. Low-power microscopic fields may be found which contain (separately and in sequence) hyaline cartilage, vacuolated cartilage, eroded cartilage, vessels and osteogenic tissues, and primary bone trabeculae surrounded by periosteal bony rings. In subsequent figures in this report (Figs. 2 et seq.), parasagittal sections of vertebral ossicles are illustrated. Higher magnifications can thus be provided of single ossicles containing both cartilage and bone. The section plane usually passes through a part of the centrum, the arch, and some of the spinous process of the 10th thoracic vertebra, as well as the proximal part of the rib and such non-osseous structures as the emerging spinal nerve root.

Histological Techniques: The majority of the fetuses were obtained by Caesarian section and injected intra-umbically with a tracer dose (5 μC) of calcium-45. They were kept alive in a warm moist chamber for at least 30 minutes after injection, with respiration occasionally being stimulated by gentle prodding. Thereafter they were fastened out straight to facilitate sagittal sectioning with a maximum of mid-plane structures and fixed in 80% alcohol (Renaud, 1959). Midway in the three-day fixation period the fetuses were bisected sagittally. Each piece was then dehydrated in three changes of

dioxane over an 18-hour period and embedded in Fisher's Tissuemat (M.P. 56° - 58.9°C) after three changes over an 8-hour period. Sections were cut at 10 microns.

In addition, other litters were obtained in which the calcium-45 tracer had reached the fetuses through placental transfer. The mothers were given daily intramuscular injections of 10 μC on days 14 through 18. Since day 14 is the earliest day of appearance of any ossification sites in the strain (Wright et al., 1958), it was intended thereby to tag all fetal bone mineral with the radioisotope. All fetuses thus obtained were examined by procedures identical with those used in the preceding group.

Autoradiography: Autoradiographs were prepared both by stripping-film and contact methods. For the former, sections were stretched and then floated on cool distilled water in a petri dish and removed to the darkroom. Pieces of Eastman Kodak's NTB autoradiographic stripping film (10 μ thickness) were cut approximately 1 x 2 inches in size and left on their cellulose backing. A piece was then slipped, emulsion side up, into the water under a floating paraffin section, an edge of the section allowed to catch on the emulsion, and the film slowly withdrawn with the section adhering flatly to the surface. Excess water was drained off, the film was set aside in a plastic holder until dry, and then stored in a light-tight box at room temperature for exposure (usually two weeks). After the exposure period the film was developed in D-19 for two minutes, rinsed in water, and fixed for twice the length of time it took to clear in freshly-made sodium thiosulfate rather than acid fixing bath, to avoid calcium loss due to acid. The films were washed for 10 minutes in running water and allowed to dry, still adhering to their cellulose backings.

Contact autoradiographs were made by 3- to 4-day exposures of sections against Eastman Kodak's Type A Industrial X-ray film. They were developed and fixed in standard x-ray solutions.

Microradiography: All sections except those mounted on stripping film were mounted on one-quarter mil Mylar® film. This film was cut in 1 by 3 inch strips, laid on glass slides, and smeared with albumin adhesive. The paraffin section was then placed on top, water was allowed to flow underneath, and the whole transferred to a warming table for stretching and drying. (Static electricity and resistance to surface wetting are the chief problems encountered in using this very thin plastic film for mounting sections.) Paraffin was removed with xylol, and the sections were again thoroughly dried before being contact autoradiographed as previously described. Following the autoradiographic exposure, the Mylar film-mounted sections were transferred to graph paper support, using cellophane tape at the edges for retention of flatness. By examination of the contact autoradiographs the region of the fetus desired for further study could be determined; the graph paper facilitated the plotting of this region and cutting of the section-and-film by iridectomy scissors into strips of width equal to the microradiographic field.

The Phillips CMR x-ray instrument was employed. By use of a spacing collar the specimen was placed 24 mm. from the target rather than the 15 mm. standard for the instrument. The gain in field diameter from 5 to 5 mm., with a corresponding increase in the number of ossicles visualized in any field, justified the longer exposures required with this greater target-to-film distance. Eastman Spectroscopic film type 649-O was used. Although its resolving power exceeds 1500 lines per mm., the conditions in the present experiment probably did not employ its full capacity. Standard exposures of three and one-half minutes were adopted, using 4 kilovolt potentials (see Results) with a 8 milliampere current. The exposure was increased to four minutes for microradiographs of sections on stripping film. This compensated for the greater thickness of the film backing and emulsion (15 μ versus 6 μ) through which the x-rays had to pass. Development was in D-19, 5 minutes, 20°C.

Further details of the principles, equipment, and procedures in microradiography are found in the report on the Cambridge Symposium on "X-ray Microscopy and Microradiography" (Coslett, Engstrom and Pattee, 1957).

Histochemical Techniques: The von Kossa test was conducted as described by McLean and Bloom (1940) who adapted this procedure for use in studies on osteogenesis. The alizarin red S (Fig. 2) was used as described by McGee-Russell (1958), using a 90-second staining time.

As mentioned earlier, a ferrocyanide procedure was also used. It should be noted that its principle differs markedly from the technique explored by McGee-Russell. In McGee-Russell's studies, ferric chloride solution was applied to the section, the ferric ion presumably replacing the calcium in the mineral deposit. Subsequent treatment with potassium ferrocyanide produced a Prussian blue reaction. McGee-Russell found it insufficiently specific, since non-mineralized protein could show a color reaction, and since it did not disclose the known presence of such salts as calcium carbonate. The stain used in the present study was devised and reported by Hurst, Hutton, and Nickolls (1951), who reversed the sequence of the reagents. According to these authors, by treating first with an ammonium-acetate buffered solution of potassium ferrocyanide, calcium ammonium ferrocyanide is formed in the tissue. Subsequent application of ferric chloride produces a Prussian blue reaction having a translucence much like that of a stain, and varying in intensity from delicate to deep blue. Since the present study appears to confirm the contention of Hurst et al. on the specificity and utility of this procedure, a set of steps derivable from the original abstract is provided here, supplemented by comments from our experience with it:

1. Prepare a solvent of 40% ethanol containing 10% (wt/vol) of ammonium acetate. Bring to pH 5.0 by addition of glacial acetic acid.
2. Add approximately 1% (wt/vol) of potassium ferrocyanide to the

buffered solvent.

3. Immerse sections in the above solution for 30 seconds to 1 minute.

4. Rinse sections in several changes of an acetate-buffered solution like that in Step 1 save for the use of 30% ethanol.

5. Immerse in 10% aqueous solution of ferric chloride for 5 minutes.

6. Dehydrate and mount as usual for permanent preparations.

The procedure offers very little difficulty. The following comments on the several steps are in order:

1. It is questionable whether precision of pH measurements can be obtained in the ethanol concentrations specified. The use of pH paper sensitive in the range 4.8 to 6.7 seemed adequate. Below approximately 5.5, it was found that very large amounts of glacial acetic acid were required to produce minor changes in pH. On the other hand, the staining reaction is not dependable at pH 6. We have routinely sought, therefore, to approximate pH 5.5 in preparing this buffer.

2. The ferrocyanide solution should be freshly prepared; we have had failures with even day-old reagent. The weighed amount of potassium ferrocyanide is added to the buffer early on the day of staining, and the resulting solution used after 2 hours but not after more than 8 hours. At room temperature crystals of ferrocyanide usually remain in the bottom of the solution throughout this period so that the 1% solution mentioned by the authors is not attained.

3. Deparaffinized glass slide or Mylar-mounted sections and loose nitrocellulose-embedded sections were equally usable. Frozen sections were not tried.

4. At least three changes of rinse are desirable; otherwise, faint deposits in non-mineralized areas result. The reason for the change to 30% ethanol is not obvious, and we have had success using the original 40% solution. Routinely, however, the 30% solution recommended by the authors is

employed. It is possible that there are slight differences in solubility which facilitate removal of excess ferrocyanide from non-mineralized areas.

5. In our material the color reaction developed completely within 30 to 45 seconds.

6. Eosin provides an attractive and useful counterstain when desired. No counterstain was used on critical sections in the present study.

Sequence of Sections: Series of 8 to 10 sections, equally free from sectioning flaws, were located in the paraffin ribbon. Even-numbered sections were mounted on 10-micron emulsion NTB stripping film, exposed, developed, and fixed as previously described, microradiographed, and stained with hematoxylin and eosin. Odd numbered sections, mounted on 1/4-mil Mylar, were autoradiographed by contact technique, microradiographed, and thereafter subjected to one of the three staining procedures. Table I shows the tests which can be performed with a minimal sequence of five sections.

RESULTS

Since the microradiographs were to be used as the common factor in comparisons, standarization of their preparation was desirable. Figures 4 to 6 show a series of microradiographs of the same specimen. The kilovoltage (and hence the wave-length) was varied to determine whether the differing penetrating capacities would affect the demonstration of mineralized sites.[4] At 3 kilovolts (Fig. 4) not only the mineral but also the non-mineralized soft tissues were visualized, and the resulting loss of contrast was objectionable. At 4 kilovolts (Fig. 5) a sharp image of mineralized regions was obtained, with only a slight image of soft tissues; this latter was of assistance in orientation. Five kilovolt x-rays penetrated the soft tissues almost completely, but even delicate mineralized structures retained their radiopacity (Fig. 6). The 4 kilovolt energy was chosen as most suitable to the study.

It may be noted that the ossicle used in this demonstration was that which was subsequently stained by the alizarin procedure (Fig. 2). The dye-lake thus produced yielded a preparation whose definition and resolution were poor compared to other procedures employed.

The von Kossa test (Fig. 7) yielded very sharp contrasts between positive and negative regions. In numerous trials it reproduced the microradiographic image of the same specimen with great fidelity (Fig. 10). The agreement extended even to the most delicate strands of mineralized cartilage matrix enclosing the lacunae of hypertrophic chondrocytes.

The stripping film autoradiograph (Fig. 8), with its underlying counterstained tissue section, showed that the sharp contrasts of the von Kossa stain and the microradiograph were not fully representative of actual calcium distribution. Dense grain patterns, indicating the site of calcifying cartilage and bone, corresponded well with the microradiograph of this section (Fig. 11). In addition, less dense but still recognizable concentrations of grains could be found at several sites beyond those whose x-ray showed mineral radiopacity.[5] Such sites were along a periosteal border (top, right) and in a concave band below the ossicle. This latter was sharply limited to the region between bone and nerve-root (seen in cross-section in the lower right quadrant of the figure). At the perineurium, the grain density dropped to background levels. A grain density above background could also be seen in the region of vacuolated cartilage (lower left of field) just in advance of the line of provisional calcification demonstrable in the microradiograph.[6]

It thus appeared that although the heavier concentrations of calcium-45 coincided well with the microradiographic and von Kossa tests, there were regions in advance of the sites thus identified, as much as 40 microns in width, which contained lesser but significant amounts of calcium-45.

The ferrocyanide reaction is illustrated in Fig. 9. It did not show the sharp contrasts between positive and negative reactions for mineral seen in microradiographs and von Kossa reactions. Instead, gradients of staining density were visible, varying from heavy to faint. All except the faint bands agreed well with the mineral shown by the microradiograph (Fig. 12). The fainter bands seemed coextensive with most of the sparser regions shown in the calcium-45 autoradiograph of the adjacent section.

DISCUSSION

Calcium-45 autoradiographs have been employed here to determine the sensitivity of several histochemical procedures recommended for localization of calcium. Such autoradiographs suggest that the optimal histochemical procedure should disclose gradients of stain density corresponding to the grain-density distribution recorded by the autoradiograph. The reliability of the histochemical procedure will obviously depend on its ability to react with calcium, in whatever state present in the tissues, and in whatever concentration.

The "calcium" tests investigated represent three classes of reactions--an indirect or calcium substitution reaction, a direct calcium reaction, and a dye-lake physico-chemical reaction.

The von Kossa test is a substitution test (Cameron, 1950), and depends on the presence of phosphate and carbonate, not calcium. As a chemical reaction, silver replaces the calcium in the bone salt, and the resultant insoluble silver phosphate/carbonate is reduced by exposure to light, producing a black metallic image. (It is possible that a physico-chemical reaction is also present, with silver ions being trapped on the apatite crystalline surfaces; the predilection of these surfaces for adsorption is well-recognized.) The close agreement between this test and the microradiograph leads support to the

concept that the von Kossa reaction locates the apatite mineral of skeletal tissues.

The authors of the ferrocyanide procedure report that the first step involves calcium directly, with the formation of an insoluble calcium ammonium ferrocyanide. Such a reaction would not be dependent on anions for recognition of calcium loci. The evidence from autoradiography is that there is actually a sparse calcium deposit at borders of advancing calcification, which exceeds the limits of the apatite bone salt demonstrated microradiographically and by the von Kossa test. Its chemical state is not known, but it remains localized in the tissue throughout the various processing. It is likely that the ferrocyanide reaction detects this calcium. There have been several demonstrations of chemical specialization just ahead of the calcified margin, the most recent being the report by Irving (1958) of a narrow pyridine-resistant sudanophil band (Sudan black B) in this region.

It should be noted that Heller-Steinberg (1951) modified the basic von Kossa procedure in such a way as to demonstrate gradients of silver density (black, gray, and brown) in place of the black-or-none reaction usually produced. It is possible that her test, involving the carefully controlled use of silver nitrate in dilute solutions saturated with silver phosphate and carbonate, may disclose calcium sites not usually visualized. The preparations apparently have the disadvantage of fading within a few days.

The alizarin dye-lake procedure tested did not allow critical distinction of calcified sites. As reported by McGee-Russell (1958), the end point is empirical, and during the reaction the dye-lake-calcium combination may become a mordant for further dye precipitation, with diffuse background staining. Similar problems have been reported with other dye-lake procedures. It is of interest, however, that Bohatirchuk (1957) has shown that Fast Green may be used as a critical stain for calcium deposits. He found agreement between

microradiographs and Fast Green-stained sites. His demonstration that microradiographs taken before and after the staining procedure were comparable implies that the reaction left the mineral substantially unchanged. His microradiographs were made at voltages approximately three times higher than those used here. It is unlikely that this more penetrating radiation (See Fig. 6) would have disclosed the minimal density sites appearing in autoradiographs and ferrocyanide stains in the present study (See Figs. 8 and 9).

Alizarin red S is commonly used in cleared whole-body preparations to show beginning ossification centers (as by Wright et al., 1958). The present study makes it clear that in bones undergoing endochondral ossification, the first alizarin stainable material is calcified cartilage, and not true bone.

The fact that a Prussian blue reaction is a common histochemical test for iron raises the question of specificity of the test devised by Hurst et al. (1951) and analyzed here. Two points may be made: (1) to detect ferric iron in tissues by application of ferrocyanide ion, pretreatment with dilute acid is essential to liberate the ferric ion from non-reactive combinations (Pearse, 1954). Although acid pre-treatment is not used in Hurst's calcium ferrocyanide procedure, the first reagent is buffered to pH 5 - 5.5. (2) If the test were showing iron under these conditions, the blue coloration should appear during the first stage, when the potassium ferrocyanide reagent is being applied. No such color develops. Similar assurances as to specificity cannot be given for the other Prussian blue and the Turnbull blue substitution tests for calcium, whose usefulness and shortcomings were analyzed by McGee-Russell (1958). Hurst et al. (1951) report that magnesium can give a positive reaction in their test.

The translucence of the Prussian blue reaction suggested its trial as a calcium-specific stain for the tissues in stripping film autoradiographs of bone-seeking radioisotopes. Von Kossa tests cannot be used, since the black

precipitate obscures the overlying autoradiographic silver grains. Unfortunately, the Prussian blue reaction cannot be used either. The autoradiographic image undergoes gradual dissolution in the ferrocyanide reagent, possibly by a reaction similar to that of Farmer's reducer (potassium ferricyanide and sodium thiosulfate) when applied to photographic negatives.

SUMMARY

1. The sensitivity and reliability of three representative histochemical tests for calcium (von Kossa, ferrocyanide, and alizarin) have been compared by applying them to vertebral ossification centers in the rat fetus.

2. The histochemical results were controlled by concurrent study of calcium-45 autoradiographs and of soft x-ray microradiographs of the same or adjacent sections.

3. Microradiographs and von Kossa-positive reactions produced essentially identical representations of mineralized bone and cartilage.

4. The von Kossa reaction coincided with high grain density regions of calcium-45 deposition in stripping-film autoradiographs but did not reflect the sparser densities.

5. The ferrocyanide reaction showed gradients of staining density corresponding in many sites with the varying degrees of radiocalcium density. Faint ferrocyanide reactions extended beyond the limits of microradiographic mineral opacity.

6. The resolution obtained with contact autoradiographs and alizarin dye-lake histological preparations was inadequate for study at high magnification.

REFERENCES

Asling, C. W., M. E. Johnston, P. W. Durbin, and J. G. Hamilton. Localization of cerium-144 in the skeletal tissues of fetal rats. University of California Radiation Laboratory Report No. 8024: 1-28, 1957.

Asling, C. W. and M. Johnston. Sensitivity of histochemical and microradiographic tests for calcification in tissues. Anat. Rec. 133: 245-246, 1959. (Abstract)

Bohatirchuk, F. P. Stain historadiography. Stain Tech. 32: 67-74, 1957.

Cameron, G. R. The staining of calcium. J. Path. Bact. 33: 929-955, 1930.

X-ray Microscopy and Microradiography. Ed. by V. E. Cosslett, Arne Engstrom and H. H. Pattee, Jr. Academic Press, New York, 1957.

Heller-Steinberg, Minnie. Ground substance, bone salts, and cellular activity in bone formation and destruction. Am. J. Anat. 89: 347-379, 1951.

Hurst, Valerie, H. E. Hutton and James Nicholls. A new histochemical reaction for calcium. J. Dent. Res. 30: 489, 1951. (Abstract)

Irving, J. T. A histological stain for newly calcified tissues. Nature 181: 704-705, 1958.

Johnston, M. E. and C. W. Asling. Histophysiology of Ca^{45} deposition in the developing skeletal tissues of the fetal rat. Rad. Research 9: 136, 1958. (Abstract)

McGee-Russell, S. M. Histochemical methods for calcium. J. Histochem. and Cytochem. 6: 22-42, 1958.

McLean, F. C. and William Bloom. Calcification and Ossification. Calcification in normal growing bone. Anat. Rec. 78: 353-359, 1940.

Pearse, A. G. E. Histochemistry Theoretical and Applied. J. and A. Churchill, London. 1954.

Renaud, S. Superiority of alcoholic over aqueous fixation in the histochemical detection of calcium. Stain Tech. 34: 267-271, 1959.

Wright, H. V., C. W. Asling, H. L. Dougherty, M. M. Nelson and H. M. Evans. Prenatal development of the skeleton in Long-Evans rats. Anat. Rec. 130: 659-672, 1956.

FOOTNOTES

1. This work was conducted jointly under the auspices of the Atomic Energy Commission and U.S.P.H. Grant No. A. 664. Portions have been reported to the International Congress of Radiation Research, (Johnston and Asling, 1958) and the American Association of Anatomists (Asling and Johnston, 1959).

2. The fetal ages are based on Day 0 starting on the morning of the day on which sperm is found in the vagina after over-night presence of the male with the female.

3. "Mylar" is a registered DuPont trademark for its brand of polyester film.

4. In this series the total radiation emitted was held constant; i.e., although the kilovoltage was varied, the product of kilovolts x milliamperes x minutes was held to 28 watt-minutes.

5. Contact autoradiographs provide images whose resolution is inadequate at higher magnification (Fig. 3). However, they are useful in establishing the location of isolated faint deposits of radioisotopes, and hence are of value in surveys at low magnification.

6. Attention must be given to the following possibilities in interpreting autoradiographs.

   (a) Scatter, related to emulsion thickness and particle energy.

   (b) Shrinkage, related to emulsion matrix and backing.

   (c) Processing artefacts, from tissue fixation through image fixation.

LEGENDS FOR ILLUSTRATIONS

Plate I. Magnification 75x except where stated.

Fig. 1. Median sagittal section of 19-day-old rat fetus, stained with von Kossa test and counterstained by periodic acid-Schiff reaction. 2x

Fig. 2. Alizarin-red S stain for mineral in 10th thoracic vertebral ossification sites.

Fig. 3. Contact autoradiograph of calcium-45 in section of vertebral ossicle; compare with the same ossicle in Figs. 9 and 12.

Figs. 4-6. Microradiographs of the ossicle shown in Fig. 2 showing the effect of varying kilovoltages (3, 4, and 5 KVP, respectively).

Plate II. Magnification 75x.

Fig. 7. Von Kossa test applied to 10th thoracic vertebral ossification sites.

Fig. 8. Stripping-film autoradiograph of calcium-45 in section adjacent to that shown in Fig. 7.

Fig. 9. Ferrocyanide test in section adjacent to that shown in Fig. 8.

Figs. 10-12. Microradiographs (4 KVP) of ossicles illustrated in Figs. 7-9, respectively.

Table I

Procedures applicable to a sequence of five histological sections.

Section Number	Autoradiograph		Microradiograph	Stain or Reaction
	Stripping-film	Contact		
1	-	X	X	Ferrocyanide
2	X	-	X	H & E
3	-	X	X	von Kossa
4	X	-	X	H & E
5	-	X	X	Alizarin red S

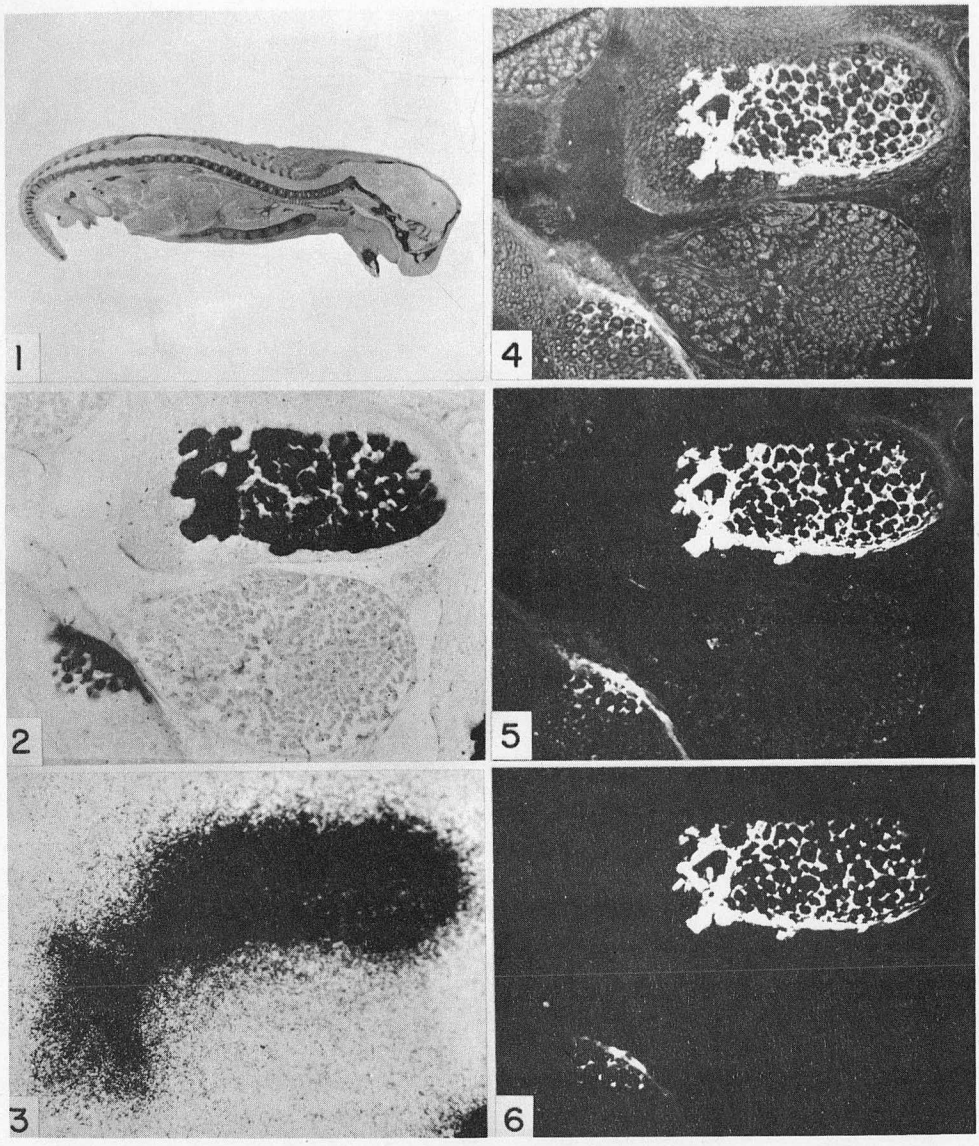

PLATE I

ZN-2302

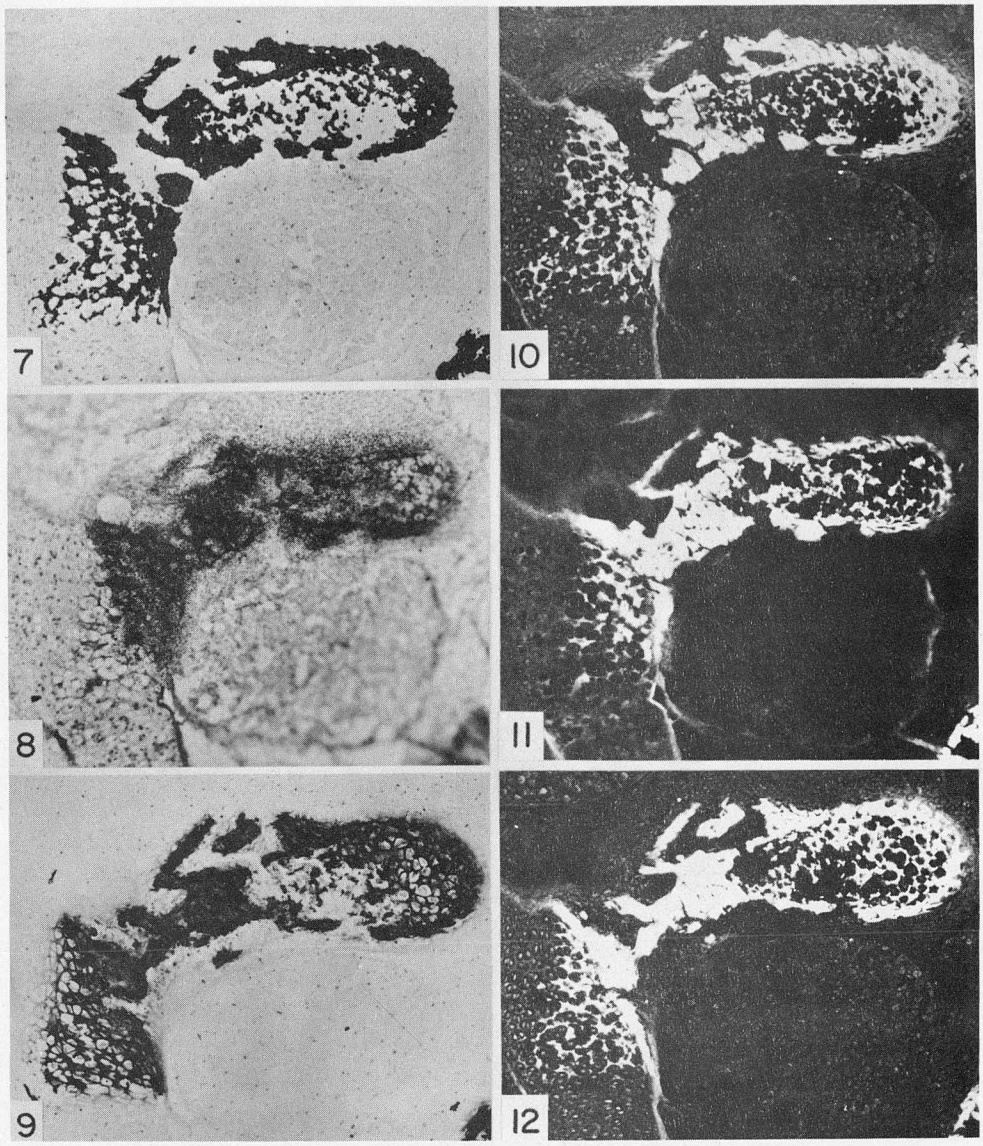

PLATE II

ZN-2303