Vessel network detection using contour evolution and color components

Daniela M. Ushizima[1], Fatima N. S. Medeiros[2], Jorge Cuadros[3] and Charles Martins[4]

[1]Lawrence Berkeley National Laboratory, Berkeley, CA, USA
[2]University of Ceara, Fortaleza, CE, Brazil
[3]University of California Berkeley, Berkeley, CA, USA
[4]University of Sao Paulo, Sao Paulo, SP, Brazil

This work was partially supported by the U.S. Department of Energy, under ContractDOE/LBNL Contract Number DE-AC02-05CH11231.

DISCLAIMER

This document was prepared as an account of work sponsored by the United States Government. While this document is believed to contain correct information, neither the United States Government nor any agency thereof, nor the Regents of the University of California, nor any of their employees, makes any warranty, express or implied, or assumes any legal responsibility for the accuracy, completeness, or usefulness of any information, apparatus, product, or process disclosed, or represents that its use would not infringe privately owned rights. Reference herein to any specific commercial product, process, or service by its trade name, trademark, manufacturer, or otherwise, does not necessarily constitute or imply its endorsement, recommendation, or favoring by the United States Government or any agency thereof, or the Regents of the University of California. The views and opinions of authors expressed herein do not necessarily state or reflect those of the United States Government or any agency thereof or the Regents of the University of California.

Vessel network detection using contour evolution and color components

Abstract— **Automated retinal screening relies on vasculature segmentation before the identification of other anatomical structures of the retina. Vasculature extraction can also be input to image quality ranking, neovascularization detection and image registration, among other applications. There is an extensive literature related to this problem, often excluding the inherent heterogeneity of ophthalmic clinical images. The contribution of this paper relies on an algorithm using front propagation to segment the vessel network. The algorithm includes a penalty in the wait queue on the fast marching heap to minimize leakage of the evolving interface. The method requires no manual labeling, a minimum number of parameters and it is capable of segmenting color ocular fundus images in real scenarios, where multi-ethnicity and brightness variations are parts of the problem.**

I. Introduction

Retinopathy damages the retina, often with blindness implications and severe vision loss or impairment. Ocular fundus image screening can support retinopathy diagnosis in several cases. Almost 100% of individuals with diabetes will present some kind of retinopathy after 15 years of illness and 60% of them will develop the proliferative case. Diabetic retinopathy is the major cause of blindness among working age adults in United States, with 20,000 diabetics to become legally blind each year, while less than 50% of them receive needed annual exam.

Research in automated image analysis of ocular fundus has reported encouraging results in retinopathy diagnosis [3]. In collaboration with optometrists, we aim at designing efficient algorithms to be incorporated to telemedicine softwares as EyePacs [1] and enable retinopathy screening from color fundus photographs. We believe that automation could be incorporated to ophthalmology routine for both nonemergency examination and screening of retinal image databases.

In previous work considering retinal screening automation, we apply mathematical morphology operators for image enhancement, segmentation of vessels and microaneurysm detection [6]. By combining successful algorithms from [13], [17] with feature extraction using intensity measurements as in Cree [3], we obtained 84% of correct classification of microaneurysms using neural networks. These tests used only DRIVE database, later we observed that the performance of such algorithms are of limited use when the task involves clinical routine image databases. The major problem is to generalize the algorithms enough to correctly identify anatomical structures of ocular fundus images, given that image brightness is correlated to skin pigmentation, iris color and ethnicity.

Morphological operators have been used to improve ocular fundus images through filtering as well as segmentation of structures [15] as vessels [17], red-lesions [7], optical disk [10], [9] and microaneurysms [2]. The reader is refered to [4], [3] for a recent review on analysis of retinal images using automated computer techniques in telemedicine screening, including the benefits and challenges of automated health care in the field of ophthalmology. Mathematical morphology (MM) based algorithms are the standard, but often generate false discontinuities, which cause errors when checking for vascular non-perfusion. On the other hand, we show that such algorithms can be suitable to elaborate initial conditions to numerical schemes as front propagation [11].

This paper introduces an algorithm using fast marching to efficiently segment the vessel network from ocular fundus images. The pipeline encloses three main steps: a) a standard procedure of shade correction to even up the background illumination due to retina reflectance variation; b) detection of source points by a rough global thresholding of the shaded corrected image; c) front propagation using a speed function calculated from a sum of top-hats over the shaded corrected image; the motivation here is to emphasize the elongated structures, using images from a 2 datasets. Particularly, we describe the application of fast marching methods to vasculature segmentation from fundus photographs and compare the results to a standard method, using cross-curvature evaluation, originally proposed by Zana and Klein [17] and revisited in several publications the past 5 years [12], [5], [3].

II. Material and methods

We test computer algorithms using ocular fundus photographs from the publicly available database DRIVE (Digital Retinal Images for Vessel Extraction at http://www.isi.uu.nl/Research/Databases/DRIVE) [14], containing 40 color images, dimensions 565 x 584 pixels, and respective manual segmentation, often used in comparisons between different segmentation methods. We also provide vascular segmentation using images from a clinical database (EyePacs), subsampled according to DRIVE images for fair comparisons. Eyepacs contains non-macular centric, with nonuniform illumination views of the eye fundus from clinical routine, kept in an online web-based program to support remote image referrals.

This section presents two algorithms for vessel segmentation: a standard technique using mathematical morphology and an original method, which uses a propagating interface to identify the vessel network from the fundus images. Both methods use mathematical morphology for shade correction and vessel contrast enhancement as a previous step (Figure

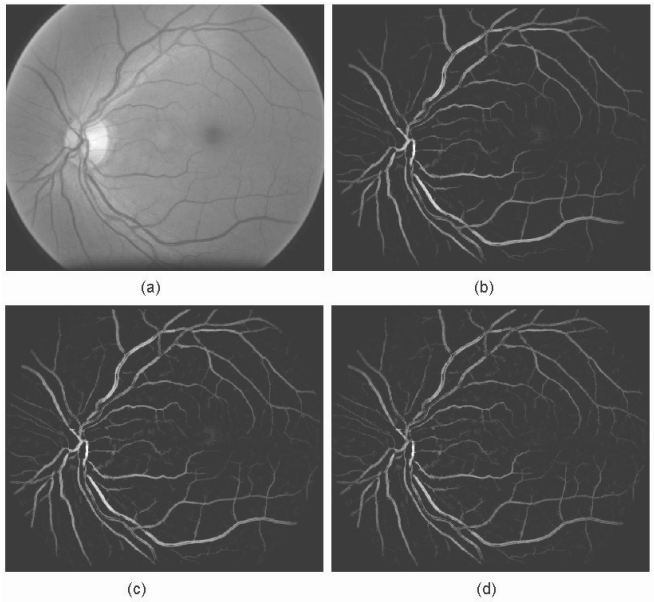

Fig. 1: Creating the speed function F: (a) green plane, (b) shade corrected image I_0, (c) opening by reconstruction I_{op} and (d) sum of top-hats I_{th}.

1), however they present a major difference in the segmentation; while the former method approximates the sign of the curvature by the sign of the Laplacian, calculated over the previous step, our method uses such step as a speed function for the evolution of a interface, separating the vessels from the background. Our approach starts with seed points to move the interface, which depends on the intensity of the speed image and, ultimately, is regulated by the color properties in the vicinity of the propagating front to improve the accuracy of the segmentation at the borders.

A. A contrario model using MM

The method for vessel segmentation using MM and curvature evaluation in [17] is often described as *a contrario* model since it focuses on eliminating what is *not* a vessel [5]. This algorithm was tailored to enhance vessel-like patterns by using a model that incorporates local linearity of the vessels, piecewise connectivity and vessel brightness modeled by a Gaussian-like profile. This is accomplished by using morphological reconstruction and top-hat transform to highlight vessels, roughly approximating a vessel segment by a straight line of n pixels (suggested: 15 pixels [17]).

Advantages of these morphological operators are the removal of noise while preserving most of the capillaries by transforming the shade corrected image (I_0) using opening by reconstruction (Eq. 1), given a rotational linear structuring elements L_i, such that $|L_i| = n$ and $L_i - L_{i-1} = 15^o$. The resulting image I_{op} is input to the sum of top-hats (I_{th}) step, which enhances vessels independently of their direction (Eq. 2).

$$I_{op} = \gamma_{I_0}^{rec}(max_i \gamma_{L_i}(I_0)), i = 1, ...12 \quad (1)$$

$$I_{th}(I) = \sum_i I_{op} - \gamma_{L_i}(I_0) \quad (2)$$

The I_{th} image representation is input for two steps in our algorithm: a) a global threshold (Otsu [8]) to select a set of source points (S) belonging to vessel parts to initialize the front evolution; b) the partial differential equation, which uses I_{th} as the speed function F to evolve S, based upon the numerical scheme presented in the next section.

B. Front propagation and color penalty

Among the several algorithms to solve equations of motion for moving interfaces using partial differential equations, fast marching methods can solve the Eikonal equation, $F|\nabla T(x, y)| = 1$, in $O(NlogN)$, where F is a speed function that depends only on the position of the front and $T(x)$ is the arrival time at each point, N is the total number of points in the computational domain.

The main idea is to propagate a front, which advances monotonically with a speed function F that never changes sign. In our approach, it models an interface S moving always outward. The position of the front at each time step of an iterative process is recorded by T, starting with $T(S) = 0$.

The implementation of this numerical scheme relies on the solution of the an upwind-scheme, which itself depends on computing the arrival time T at each point X given a neighborhood. The upwind-scheme discretizes the gradient ∇T by calculating:

$$max(D_{i,j}^{-x}T, D_{i,j}^{+x}T)^2 + max(D_{i,j}^{-y}T, D_{i,j}^{+y}T)^2 = \frac{1}{F_{i,j}^2} \quad (3)$$

where D^- and D^+ are the backward and forward finite differences, namely:

$$D_{i,j}^{-x} = \frac{T_{i,j} - T_{i-1,j}}{\Delta x} \quad (4)$$

analogously defined for y.

Starting with the seeds in S from the binarization method, we can assign $T(x_i, y_i) = 0$ to the n pixels at the position x_i, y_i, for $i \in [1, n]$. Each of these n seeds is embedded in the functions Φ^i, $(1 <= i <= n)$, hereafter called fronts. The front movement is limited by the position of other fronts, such that every time a front is moved one step, the outcome is considered as a trial, preventing the fronts from crossing. The step status updates from trial to definitive state, also known as "burnt" state, after selecting the minimum trial value from a heap, the data structure to organize the arrival times T. The efficiency of the algorithm proposed by Sethian [11] is the search for the minimum trial value using a heap.

Preliminary results showed that the application of fast marching to ocular fundus vessel segmentation depended on minimizing the "leakage effect" of the algorithm [16]. This effect corresponds to the accuracy during the interface evolution to determine the borders of the vessel, a problem that stems from essentially local properties to evolve the functions Φ^i. Our contribution relies on adding a step to the algorithm, so that we can impose local relationships

regarding color similarity of the pixels. The algorithm can be summarized as the following:

1) select trial pixel p such as T_p=min(trial-list);
2) solve the quadratic equation as in Eq.3 to update T_p;
3) select neighborhood to go to trial list based on position;
4) add neighbors to trial-list if satisfies color similarity;
5) if not satisfy color similarity, then pixel is not part of vessel;
6) go back to step (1) until trial-list is empty or converged (no changes to the trial-list).

The color similarity calculation transforms the RGB color of p into its respective CIELab coordinates, such that color similarities correspond to small distances in the color space.

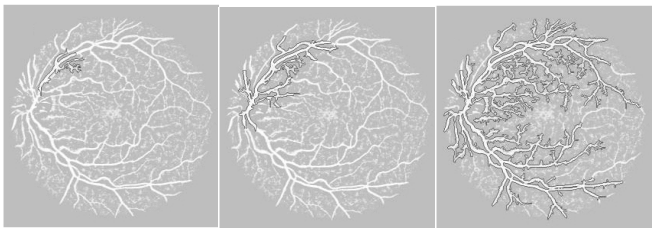

(a) (b) (c)

Fig. 2: Evolution of the front during vasculature segmentation of ocular fundus.

III. Results and Discussion

We compared the performance of the algorithms by calculating the sensitivity ($SE = TP/(TP+FN)$), specificity ($TN/(TN+FP)$) and predictive value ($PV = TP/(TP+FP)$) using the 40 available images and manual segmentations from DRIVE dataset [14]. These measurements are based in the number of true positives (TP), false positives (FP), true negatives (TN) and false negatives (FN), calculated by comparing the manual segmentation of each of the 40 images to the output of the algorithms, similarly to Figure 2. The relative performance comparison, illustrated in Figure 4, presents the efficacy of the proposed wave propagation (WP) method, which is more sensitive, more specific for most of the images and presented higher prediction value. The method using MM-only [17] performed poorly, although the vessel detection in few images presented higher specificity - this happened due to the low sensitivity of the algorithm in such cases. We also observed that there is less fluctuations of SE, SP and PV among images by using proposed FM algorithm in comparison with the MM-only approach.

Our method presents the advantage of maintaining the connectivity of the vessels (Fig.3), lower level of false negatives and proposes the use of color similarity to minimize mistakes at the vessel boundaries. In addition, we illustrate preliminary results using clinical routine image database in Figure 5, where the magenta-transparent color present the result of segmentation over the original image. The current computing time per image is approximately 45 seconds, at least 50% faster than the MM-only approach, both using an unoptimized Matlab code and running in a computer with Intel Centrino Duo 2.16GHz, 2GB RAM.

Although we showed improved accuracy in comparison to a standard method for vasculature segmentation [17], further improvements must still account for the leakage effect of the fast marching at the capillary level, here compromised due to imprecision of our speed function. Also, other thresholding schemes should be tested, since this is a key step in guaranteeing vessel segmentation, particularly in cases of non-perfusion in the vessel network. We are currently working on an approach that considers orientation of the propagation front to be considered during its evolution, in addition to the description of the segmented vessel area in terms of viscosity parameters.

IV. Acknowledgments

This work was partially supported by CNPq and the Applied Mathematical Science subprogram of the Office of Energy Research, U.S. Department of Energy, under Contract Number DE-AC03-76SF00098.

References

[1] J. Cuadros and G. Bresnick. EyePACS: an adaptable telemedicine system for diabetic retinopathy screening. *J Diabetes Sci Technol*, 3(3):509–516, May 2009.

[2] A. D. Fleming, S. Philip, K. A. Goatman, J. A. Olson, and P. F. Sharp. Automated microaneurysm detection using local contrast normalization and local vessel detection. *IEEE Trans Med Imag*, 25(9):1223–1232, 2006.

[3] H. Jelinek and M. J. Cree, editors. *Automated Image Detection of Retinal Pathology* . CRC Press, 2009.

[4] H. F. Jelinek, M. J. Cree, J. J. G. Leandro, J. ao V. B. Soares, R. M. Cesar, and A. Luckie. Automated segmentation of retinal blood vessels and identification of proliferative diabetic retinopathy. *J. Opt. Soc. Am. A*, 24(5):1448–1456, 2007.

[5] D. Lesage, E. D. Angelini, I. Bloch, and G. Funka-Lea. A review of 3d vessel lumen segmentation techniques: Models, features and extraction schemes. *Medical Image Analysis*, 13(6):819 – 845, 2009.

[6] C. I. Martins, R. M. Veras, G. L. Ramalho, F. N. Medeiros, and D. Ushizima. Automatic microaneurysm detection and characterization through digital color fundus images. In *SBRN*, 2008.

[7] M. Niemeijer, B. van Ginneken, J. Staal, M. Suttorp Schulten, and M. Abramoff. Automatic detection of red lesions in digital color fundus photographs. *IEEE Trans Med Img*, 24(5):584–592, May 2005.

[8] N. Otsu. A threshold selection method from gray-level histograms. *IEEE Transactions on Systems, Man, and Cybernetics*, 9(1):62–66, 1979.

[9] A. W. Reza, C. Eswaran, and S. Hati. Automatic tracing of optic disc and exudates from color fundus images using fixed and variable thresholds. *J. Med. Syst.*, 33(1):73–80, 2009.

[10] S. Sekhar, W. Al-Nuaimy, and A. K. Nandi. Automated localisation of retinal optic disk using hough transform. *ISBI*, pages 1577–1580, 2008.

[11] J. A. Sethian. *Level Set Methods and Fast Marching Methods: Evolving Interfaces in Computational Geometry, Fluid Mechanics, Computer Vision, and Materials Science*. Cambridge University Press, 2 edition, June 1999.

[12] M. Sofka and C. V. Stewart. Retinal vessel centerline extraction using multiscale matched filters, confidence and edge measures. *IEEE TMI*, 25:1531–1546, 2006.

[13] T. Spencer, J. A. Olson, K. C. McHardy, P. F. Sharp, and J. V. Forrester. An image-processing strategy for the segmentation and quantification of microaneurysms in fluorescein angiograms of the ocular fundus. *Comput. Biomed. Res.*, 29(4):284–302, 1996.

[14] J. Staal, M. Abramoff, M. Niemeijer, M. Viergever, and B. van Ginneken. Ridge-based vessel segmentation in color images of the retina. *IEEE Trans Med Img*, 23(4):501–509, April 2004.

[15] K. Tobin, E. Chaum, and G. V. P. Automatic detection of red lesions in digital color fundus photographs. *IEEE Trans Med Img*, 26(12):1529–1739, 2007.

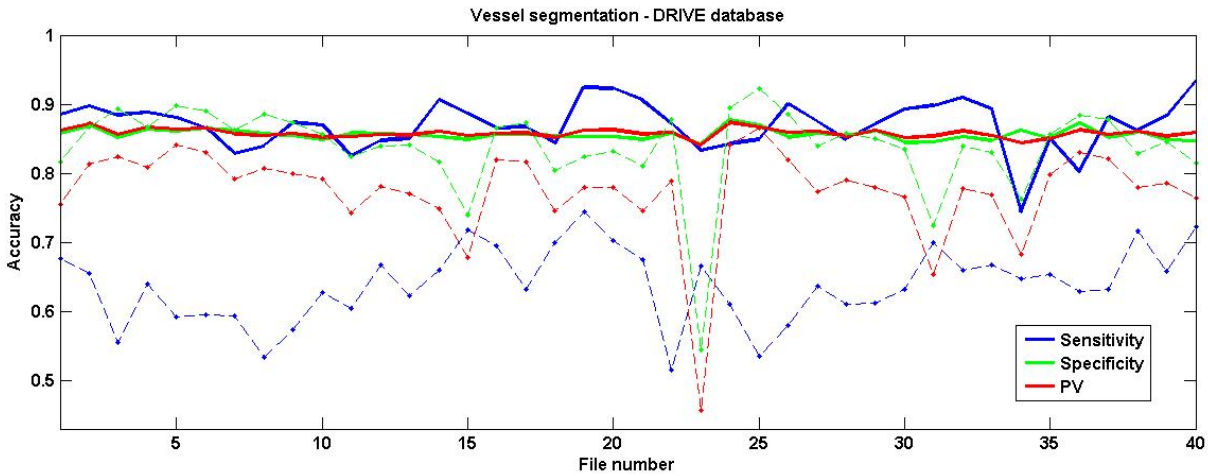

Fig. 3: Sensitivity, specificity and predictive values of the wave propagation method (solid lines) and the mathematical morphology-only (dashed lines) method applied to 40 images from DRIVE database.

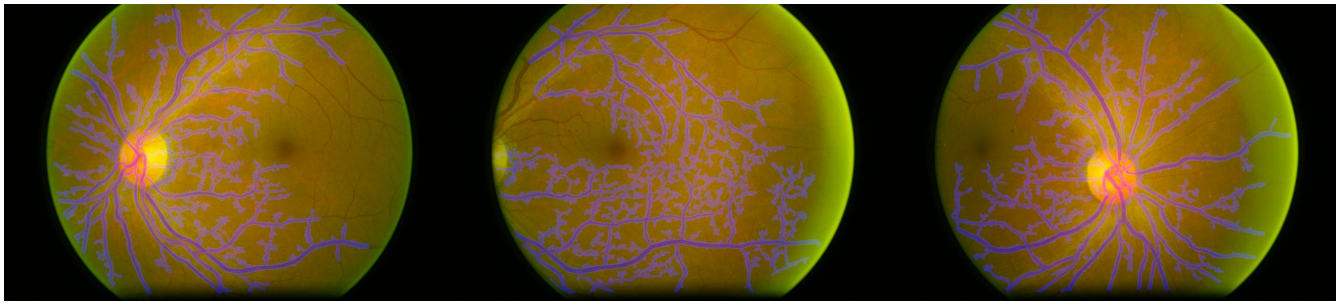

(a) (b) (c)

Fig. 4: Segmentation of ocular fundus using clinical routine images: vessel detection under brightness variations and for non-caucasians.

[16] D. Ushizima and F. N. S. Medeiros. Retinopathy diagnosis from ocular fundus image analysis. In *Annual Meeting of the Society for Industrial and Applied Mathematics, Conference on Imaging Science*, Chicago, IL, April 2010.

[17] F. Zana and J. Klein. Segmentation of vessel-like patterns using mathematical morphology and curvature evaluation. *IEEE Trans Imag Proc*, 10(7):1010–1019, July 2001.