LBL-28252

Lawrence Berkeley Laboratory
UNIVERSITY OF CALIFORNIA

Presented at the First International Conference on
Radiosurgery, a Neurosurgical Approach to
Intracranial Lesions, Charlottesville, VA,
May 1–5, 1989

Clinical Results of Stereotactic Heavy-Charged-Particle Radiosurgery for Intracranial Arteriovenous Malformations

J.I. Fabrikant, R.P. Levy, K.A. Frankel, M.H. Phillips,
J.T. Lyman, G.K. Steinberg, R.L. DeLaPaz, M.P. Marks,
and F.Y.S. Chuang

December 1989

Donner Laboratory
Biology & Medicine Division

LOAN COPY
Circulates
for 2 weeks
Bldg. 50 Library.
Copy 2
LBL-28252

Prepared for the U.S. Department of Energy under Contract Number DE-AC03-76SF00098.

DISCLAIMER

This document was prepared as an account of work sponsored by the United States Government. While this document is believed to contain correct information, neither the United States Government nor any agency thereof, nor the Regents of the University of California, nor any of their employees, makes any warranty, express or implied, or assumes any legal responsibility for the accuracy, completeness, or usefulness of any information, apparatus, product, or process disclosed, or represents that its use would not infringe privately owned rights. Reference herein to any specific commercial product, process, or service by its trade name, trademark, manufacturer, or otherwise, does not necessarily constitute or imply its endorsement, recommendation, or favoring by the United States Government or any agency thereof, or the Regents of the University of California. The views and opinions of authors expressed herein do not necessarily state or reflect those of the United States Government or any agency thereof or the Regents of the University of California.

CLINICAL RESULTS OF STEREOTACTIC HEAVY-CHARGED-PARTICLE RADIOSURGERY FOR INTRACRANIAL ARTERIOVENOUS MALFORMATIONS

Jacob I. Fabrikant, Richard P. Levy, Kenneth A. Frankel, Mark H. Phillips, John T. Lyman, Gary K. Steinberg, Robert L. DeLaPaz, Michael P. Marks, Frank Y. S. Chuang

Research Medicine and Radiation Biophysics
Lawrence Berkeley Laboratory
1 Cyclotron Road
Berkeley, CA

Presented at the 1st International Conference, "Radiosurgery, a Neurosurgical Approach to Intracranial Lesions", University of Virginia, Charlottesville, 1-5 May 1989.

Research was supported by Office of Health and Environmental Research, U.S. Department of Energy Contract DE-AC03-76SF00098.

CLINICAL RESULTS OF STEREOTACTIC HEAVY-CHARGED-PARTICLE RADIOSURGERY FOR INTRACRANIAL ARTERIOVENOUS MALFORMATIONS [1]

Jacob I. Fabrikant[2], Richard P. Levy[3], Mark H. Phillips[4], Kenneth A. Frankel[5], John T. Lyman[6], Gary K. Steinberg[†7], Robert L. DeLaPaz[†8], Michael P. Marks[†9], and Frank Y. S. Chuang

Donner Laboratory, Lawrence Berkeley Laboratory, University of California, Berkeley, CA and [†]Stanford University Medical Center, Stanford, CA

INTRODUCTION

At Lawrence Berkeley Laboratory, we have developed the method of stereotactic heavy-charged-particle (helium-ion) Bragg peak radiosurgery for treatment of surgically-inaccessible intracranial arteriovenous malformations (AVMs) [2,3,5]. This report describes patient selection, treatment method, clinical and neuroradiologic results and complications encountered in 322 patients since 1980.

METHOD

Patient selection. Prospective patients with surgically-inaccessible AVMs are considered to be candidates for stereotactic radiosurgery if they have a history of intracranial hemorrhage, nonhemorrhagic neurologic dysfunction, intractable vascular headaches or refractory seizures.

Stereotactic radiosurgery treatment method. The method of helium-ion radiosurgery has been described in detail previously [2,3,5]. A removable noninvasive thermoplastic mask, stereotactic frame, and integrated stereotactic patient positioner have been developed for patient immobilization and stereotactic localization of the AVM (Figure 1). This system permits precise correlation and data transfer between sequential stereotactic cerebral angiography and stereotactic computerized tomography (CT) and magnetic resonance image (MRI) scans [6]. CT scan data

[1]Research supported by the Director, Office of Energy, Health and Environmental Research of the United States Department of Energy under Contract DE-ACO3-76SF00098.

[2]Professor of Radiology, University of California, San Francisco and Berkeley
[3]Medical Scientist, Lawrence Berkeley Laboratory
[4]Staff Scientist, Lawrence Berkeley Laboratory
[5]Staff Scientist, Lawrence Berkeley Laboratory
[6]Professor of Radiation Oncology, University of California, San Francisco
[7]Assistant Professor of Neurosurgery, Stanford University
[8]Associate Professor of Radiology (Neuroradiology), Stanford University
[9]Assistant Professor of Radiology (Neuroradiology), Stanford University

are used to identify and compensate for inhomogeneities in the tissues traversed by the charged-particle beams and to calculate the dose distribution in each patient [1]. The helium-ion beam is shaped by individually-fabricated apertures to conform precisely to the contours of the AVM and to any cross-section width from 4 to 80 mm. The range of the Bragg ionization peak and the width of the peak are determined by appropriate absorbers in the beam path (Figure 1). Thus, each beam is tailored to place a three-dimensional high dose region of desired shape stereotactically within the brain. Multiple entry angles and beam ports are chosen so that the high-dose Bragg peak regions of the individual beams intersect within the AVM target [5]. (The treatment planning procedure is described in a separate report of this symposium).

Treatment dose and fractionation. The periphery of the AVM is enclosed by the 90% isodose contour. Dose fall-off to less than 10% of the maximum dose occurs within 4 to 6 mm of the target distally, and within 2 to 3 mm along the lateral margins of the helium-ion beam [3]. Based on approved multi-institutional research protocols, maximum central (100%) doses of 45 GyE [10] were used initially. As part of dose-de-escalation protocols to determine the lowest effective dose, subsequent patients were treated with progressively lower doses. Currently, maximum central doses of 15 to 25 GyE are used, based on the size, shape and location of the AVM. Smaller or supratentorial AVMs are treated with higher doses than larger or brainstem lesions. Densely packed AVMs are treated with higher doses than those loosely intertwined with normal brain tissue. Treatment is given in 1 or 2 daily fractions, with 3 to 5 coplanar or noncoplanar beams per fraction. Lesions less than 4,000 mm^3 are generally treated in 1 d, larger lesions in 2 d. Each fraction requires less than 1 h of patient positioning and immobilization, mostly to verify positioning, and each port requires about 1 min of irradiation. A gradually tapering 2 wk course of low-dose dexamethasone is begun 1 d prior to treatment. All patients are treated on an ambulatory basis.

Patient followup. Patients are examined on a regular follow-up basis. Cerebral angiography is performed at 12-mo intervals until the AVM has been completely obliterated, or has stabilized. MRI scanning is performed at 6-mo intervals, in order to assess the vascular response and to identify early or delayed radiation injury and/or edema in the brain, and to guide appropriate management. Patients with angiographically-occult vascular malformations are followed by MRI scanning at 6-mo intervals; follow-up angiography is not performed.

RESULTS

Patient selection. We have thus far treated 322 patients (158 males, 164 females)

[10]GyE = Gy equivalent. A relative biologic effectiveness (RBE) of 1.3 is assumed for the helium-ion Bragg peak.

aged 6 to 69 y; 47 patients were 18 y or younger. There were 152 patients with AVMs in the cerebral hemispheres, primarily involving eloquent regions of motor or speech function; 95 had AVMs in the thalamus, basal ganglia, internal capsule or corpus callosum; 42 in the brainstem; 21 in the cerebellum; and 12 in the vein of Galen, choroid plexus or other locations. There were 291 angiographically-demonstrable AVMs and 31 angiographically-occult vascular malformations (AOVMs); volumes ranged from 80 mm^3 to 60,000 mm^3.

All patients were neurologically symptomatic. Intracranial hemorrhage occurred in 45% of patients. Other presenting manifestations included headaches (40%), seizures (23%), nonhemorrhagic neurologic dysfunction (20%), and hemorrhage from associated arterial aneurysms (5%). Many patients had some combination of these.

The majority of patients had no interventional therapy prior to stereotactic radiosurgery. Many patients had some form of AVM surgery (29%) and/or interventional neuroradiologic procedure (21%) before radiosurgery. Some patients had one or more adjunct surgical procedures (e.g., arterial aneurysm repair (5%), shunt placement (4%), hematoma evacuation (2%) not intended to result in any decrease in AVM size or blood flow. Various combinations of multiple therapeutic interventions were carried out in many patients before radiosurgery.

Clinical results. All patients completed the course of stereotactic neuroradiologic evaluation and treatment without difficulty. None required sedation or anesthesia during the radiosurgical treatment, although smaller children did receive general anesthesia during their diagnostic stereotactic cerebral angiograms.

Most patients (75%) have remained normal or improved to normal neurologic status following stereotactic radiosurgery; 15% have fixed neurologic deficits, unchanged from before treatment; 10% have worsened.

Neuroradiologic results. For complete vascular obliteration, there is a relationship of dose and volume primarily, and location only secondarily. When the entire arterial phase of the AVM has been targeted for radiosurgery, the incidence of complete AVM obliteration 2 y post-treatment is: 90 to 95% for volumes $\leq$ 4,000 mm^3, 80 to 85% for volumes $>$ 4,000 mm^3 and $\leq$ 14,000 mm^3, and 80 to 85% for volumes $>$ 14,000 mm^3. The total obliteration rate for all volumes up to 60,000 mm^3 is approximately 85% (Figures 2 and 3). When radiosurgery was limited to the earliest-filling arterial nidus, many patients had an incomplete response. In this subset of patients, we frequently observed complete obliteration of the radiosurgically-treated volume with an unchanged lesion at the periphery; this left undesirable shunts which require retreating. Angiographic changes of progressive vascular obliteration have been observed to continue beyond 24 mo in a few cases. The interpretation of follow-up MRI scans for AOVMs following radiosurgery is unresolved, and is the subject of continuing investigation in our laboratory. (The results of radiosurgery of AOVMs are discussed in a separate report of this symposium).

Hemorrhage. Intracranial hemorrhage from a treated AVM following radiosurgery occurred in 6.5% of patients; of these, 60% had hemorrhaged prior to radiosurgery. Of the patients who bled after treatment, 80% hemorrhaged within the first 14 mo after radiosurgery. A few patients hemorrhaged after treatment from previously unrecognized arterial aneurysms that had been hidden deep within the AVM.

Sequelae and complications. Complications are scored very conservatively; any definite or possible sequelae of radiosurgery are considered to be complications, even if functional impairment is minimal or temporary. Some neurologic dysfunction occurred in 15% of patients, nearly all in the earlier high-dose patient group. More than half of these patients have had complete or nearly complete return to their pre-radiosurgery condition. Moderate or severe symptomatic (reversible or irreversible) vasogenic edema has occurred in 8% of cases; symptomatic occlusion of normal vessels, 2 to 3%; permanent late delayed radiation injury, 1%. Overall serious and permanent neurologic complications have occurred within 2 y after treatment in approximately 5 to 6% of cases in the earlier high-dose group, but appear to be in the range of 2 to 3% at current lower doses. There has been no immediate treatment morbidity. No deaths have occurred from the radiation procedure. (The sequelae and complications are discussed in a separate report of this symposium).

DISCUSSION

Clinical and neuroradiologic results. The physical characteristics of heavy-charged-particle beams are uniquely advantageous for the radiosurgical treatment of discrete and defined intracranial lesions [7]. Studies in this laboratory have demonstrated that the radiation dose with this method to normal brain structures adjacent to and remote from the AVM is relatively low, particularly when compared to photon irradiation techniques; this difference appears especially marked in the treatment of larger AVMs (Figure 3) [7]. Bragg peak radiosurgery can be used with precision to treat eccentric and irregular AVMs of very large size, as well as to deliver extremely sharp focal beams accurately to small brainstem lesions. We consider the clinical and neuroradiologic results in this series of 322 patients with high-risk deep AVMs to be favorable. Stereotactic heavy-charged-particle radiosurgery has successfully obliterated a majority of inoperable AVMs, while effecting satisfactory protection of adjacent brain structures.

Sequelae and complications. The sequelae and complications encountered in this series, even though scored very conservatively, compare favorably with the potential risks of operative intervention of surgically-accessible AVMs or the spontaneous risk of progressive neurologic deficit in this patient group [4]. The incidence of sequelae is not solely dose-dependent nor confined to the high-dose group. Delayed radiation sequelae may be manifested by enhanced vascular permeability and vasogenic

edema. Such edema is usually asymptomatic and an incidental finding on follow-up MRI scanning; it can remain evident for up to 2 y and more, especially in the deep white matter, and then slowly regress to a normal or near-normal state. If edema is massive or present in sensitive and confined central brain structures, it may cause transient or permanent neurologic impairment. Prompt treatment with corticosteroids has frequently arrested or reversed this process and associated neurologic dysfunction. Irreversible neurologic damage can occur if the radiosurgical treatment induces occlusion of normal vessels and consequent focal infarction, especially in the central nuclei or brainstem [5]. Histologically-confirmed radiation necrosis in this series has been rare, limited to a few patients in the earlier higher-dose group; however, additional cases may have been classified as severe vasogenic edema.

CONCLUSIONS

Comparison of clinical results of different radiosurgical procedures and clinical patient series requires the establishment of common measurable parameters based on defined protocols. Confounding variables include patient selection criteria, AVM size and location, treatment dose, prior therapeutic intervention, duration of follow-up, and threshold for classification of sequelae and complications. The optimal dose must be determined for radiosurgical treatment of AVMs in various locations within the brain, in order to improve the cure rate, protect against future intracranial hemorrhage and minimize potential adverse sequelae of the radiation treatment.

References

[1] G. T. Y. Chen, R. P. Singh, J. R. Castro, J. T. Lyman, and J. M. Quivey. Treatment planning for heavy ion radiotherapy. Int J Radiat Oncol Biol Phys 5:1809-1819, 1979.

[2] J. I. Fabrikant, K. A. Frankel, M. H. Phillips, and R. P. Levy. Stereotactic heavy charged-particle Bragg peak radiosurgery for intracranial arteriovenous malformations. In Edwards, M. S. B. & Hoffman, H. J. (eds): Cerebral Vascular Diseases in Children and Adolescents, Williams & Wilkins, Baltimore, 1989, pp 389-409.

[3] J. I. Fabrikant, J. T. Lyman, and K. A. Frankel. Heavy charged-particle Bragg peak radiosurgery for intracranial vascular disorders. Radiat Res [Suppl] 104:S244-S258, 1985.

[4] R. C. Heros and Y.-K. Tu. Is surgical therapy needed for unruptured arteriovenous malformations? Neurology 37:279-286, 1987.

[5] R. P. Levy, J. I. Fabrikant, K. A. Frankel, M. H. Phillips, and J. T. Lyman. Stereotactic heavy-charged-particle Bragg peak radiosurgery for the treatment of intracranial arteriovenous malformations in childhood and adolescence. Neurosurgery 24:841-852, 1989.

[6] M. H. Phillips, K. A. Frankel, J. T. Lyman, J. I. Fabrikant, and R. P. Levy. Heavy-charged-particle stereotactic radiosurgery: cerebral angiography and CT in the treatment of intracranial vascular malformations. Int J Radiat Oncol Biol Phys, 1989 (in press).

[7] M. H. Phillips, K. A. Frankel, J. T. Lyman, J. I. Fabrikant, and R. P. Levy. Comparison of different radiation types and irradiation geometries in stereotactic radiosurgery. Int J Radiat Oncol Biol Phys, 1989 (in press).

FIGURE LEGENDS

Figure 1: Stereotactic heavy charged particle Bragg peak radiosurgery system illustrating beam delivery and dose localization methods, patient immobilization apparatus (ISAH), stereotactic frame and immobilizing mask, and compensator and beam-shaping aperture in place for treatment of an intracranial AVM. (From R. P. Levy, J. I. Fabrikant, K. A. Frankel, M. H. Phillips, and J. T. Lyman: Stereotactic heavy-charged-particle Bragg peak radiosurgery for the treatment of intracranial arteriovenous malformations in childhood and adolescence. Neurosurgery 24:841-852, 1989.)

Figure 2: Cerebral angiograms of a large left temporal AVM supplied by branches of the anterior and posterior circulations; 38-y-old male. **Upper**, AVM is supplied by hypertrophied feeding vessels from the middle cerebral artery and posterior cerebral artery (anterior and posterior temporal branches). The vascular steal is prominent. **Lower**, 12 mon after stereotactic radiosurgery there is complete obliteration of the AVM and a decrease in the size of the feeding vessels. Normal cerebral blood flow has been restored; the vascular steal is absent. The patient is neurologically normal (cf Figure 3).

Figure 3: Sagittal plane two-dimensional treatment plan (isodose contours on reconstructed CT scan) for stereotactic heavy-charged-particle Bragg peak radiosurgery of the intracranial AVM illustrated in Figure 2. The target volume was 54,000 mm^3 and dose localization and optimal dose distribution was accomplished using the "spread-out" Bragg peak of a 230 MeV/amu helium ion beam, and conformal therapy using compensators and beam-shaping apertures. The patient was treated in 2 daily fractions to a total dose of 27 GyE.

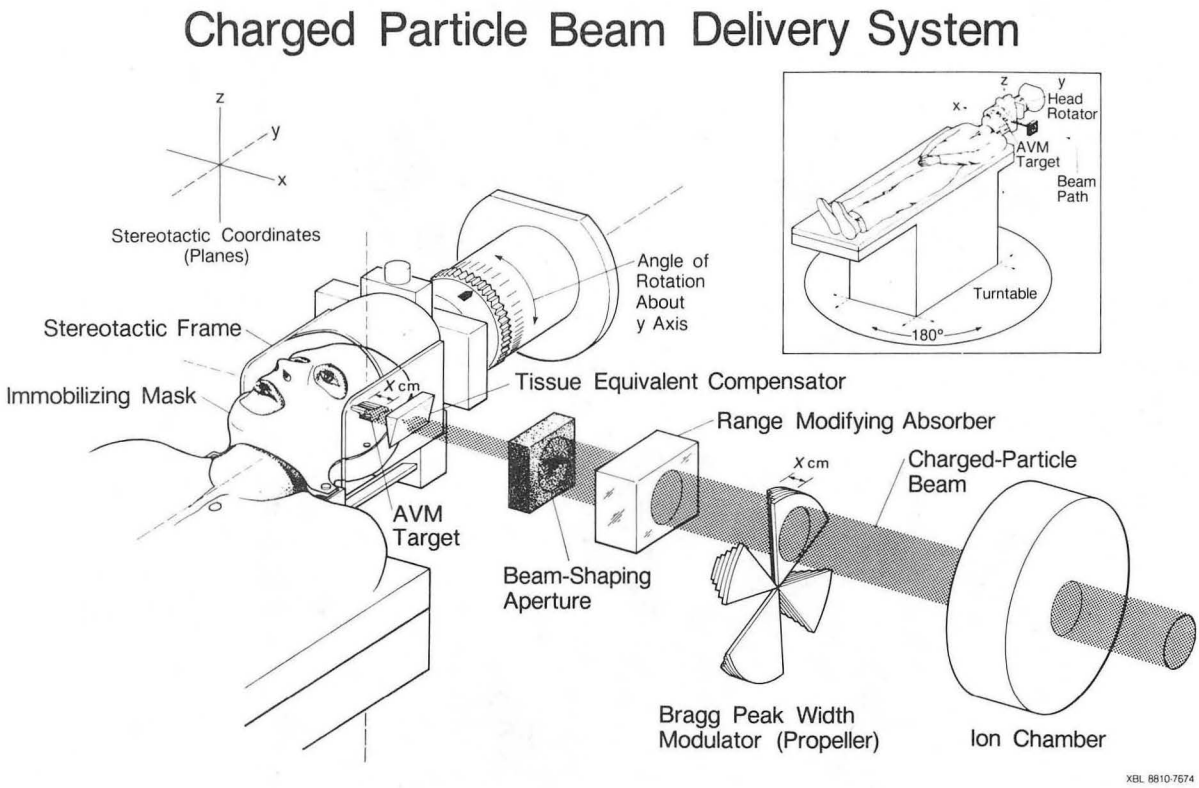
Charged Particle Beam Delivery System
z
y
x
Stereotactic Coordinates
(Planes)
Stereotactic Frame
Immobilizing Mask
X cm
AVM
Target
Angle of
Rotation
About
y Axis
Tissue Equivalent Compensator
Range Modifying Absorber
Beam-Shaping
Aperture
X cm
Charged-Particle
Beam
Bragg Peak Width
Modulator (Propeller)
Ion Chamber
z
y
x
Head
Rotator
AVM
Target
Beam
Path
Turntable
180°
XBL 8810-7674

Figure 1

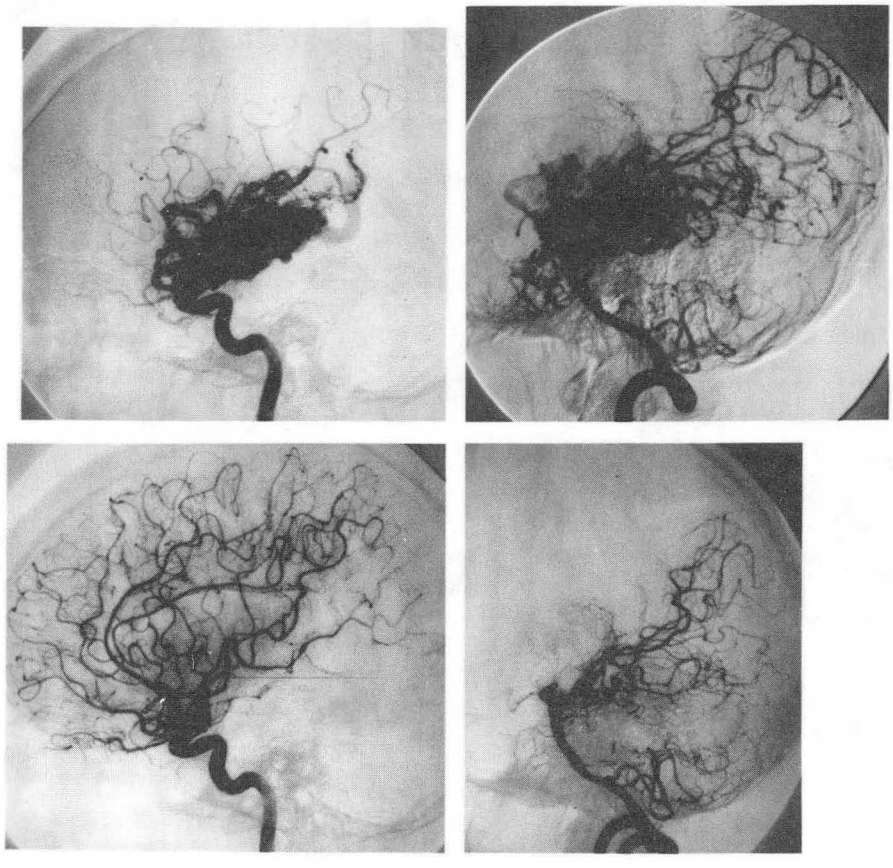

XBB 876-5281

Figure 2

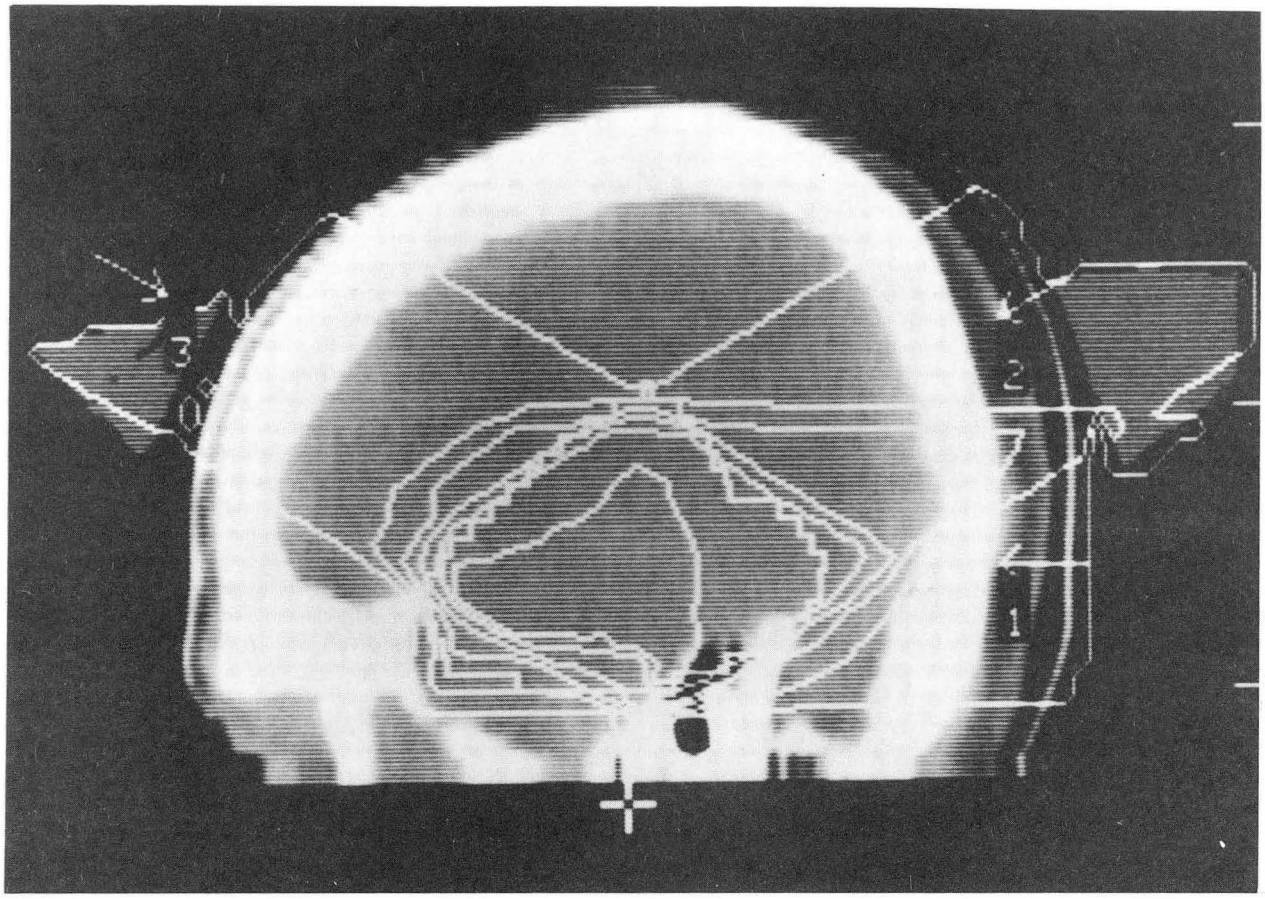

XBB 878-6973

Figure 3

LAWRENCE BERKELEY LABORATORY
TECHNICAL INFORMATION DEPARTMENT
1 CYCLOTRON ROAD
BERKELEY, CALIFORNIA 94720