Lawrence Berkeley Laboratory
UNIVERSITY OF CALIFORNIA

To be published as a chapter in *Radiosurgery Updates*,
E. Alexander, Ed., Karger, Cambridge, MA, June 1990

Heavy-Charged-Particle Radiosurgery of the Pituitary Gland: Clinical Results of 840 Patients

R.P. Levy, J.I. Fabrikant, K.A. Frankel, M.H. Phillips, J.T. Lyman,
J.H. Lawrence, C.A. Tobias

June 1990

Donner Laboratory
Biology & Medicine Division

LOAN COPY
Circulates
for 4 weeks
Bldg. 50 Library.
LBL-31309
Copy 2

Prepared for the U.S. Department of Energy under Contract Number DE-AC03-76SF0009

DISCLAIMER

This document was prepared as an account of work sponsored by the United States Government. Neither the United States Government nor any agency thereof, nor The Regents of the University of California, nor any of their employees, makes any warranty, express or implied, or assumes any legal liability or responsibility for the accuracy, completeness, or usefulness of any information, apparatus, product, or process disclosed, or represents that its use would not infringe privately owned rights. Reference herein to any specific commercial products process, or service by its trade name, trademark, manufacturer, or otherwise, does not necessarily constitute or imply its endorsement, recommendation, or favoring by the United States Government or any agency thereof, or The Regents of the University of California. The views and opinions of authors expressed herein do not necessarily state or reflect those of the United States Government or any agency thereof or The Regents of the University of California and shall not be used for advertising or product endorsement purposes.

Lawrence Berkeley Laboratory is an equal opportunity employer.

DISCLAIMER

This document was prepared as an account of work sponsored by the United States Government. While this document is believed to contain correct information, neither the United States Government nor any agency thereof, nor the Regents of the University of California, nor any of their employees, makes any warranty, express or implied, or assumes any legal responsibility for the accuracy, completeness, or usefulness of any information, apparatus, product, or process disclosed, or represents that its use would not infringe privately owned rights. Reference herein to any specific commercial product, process, or service by its trade name, trademark, manufacturer, or otherwise, does not necessarily constitute or imply its endorsement, recommendation, or favoring by the United States Government or any agency thereof, or the Regents of the University of California. The views and opinions of authors expressed herein do not necessarily state or reflect those of the United States Government or any agency thereof or the Regents of the University of California.

LBL-31309

Heavy-Charged-Particle Radiosurgery of the Pituitary Gland: Clinical Results of 840 Patients

R.P. Levy, J.I. Fabrikant, K.A. Frankel, M.H. Phillips, J.T. Lyman,
J.H. Lawrence, and C.A. Tobias

Donner Pavilion and Donner Laboratory
Research Medicine and Radiation Biophysics Division
Lawrence Berkeley Laboratory
University of California
Berkeley, CA 94720

June 1990

This report has been reproduced directly from the best available copy.

This research was supported by the Director, Office of Energy Research, Office of health and Environmental Research, Medical Applications Division, of the U.S. Department of Energy under Contract No. DE-AC03-76SF00098.

HEAVY-CHARGED-PARTICLE RADIOSURGERY OF THE PITUITARY GLAND: CLINICAL RESULTS OF 840 PATIENTS[1]

Richard P. Levy, M.D., Jacob I. Fabrikant, M.D., Ph.D., Kenneth A. Frankel, Ph.D., Mark H. Phillips, Ph.D., John T. Lyman, Ph.D., John H. Lawrence, M.D., Cornelius A. Tobias, Ph.D.

Donner Pavilion and Donner Laboratory, Lawrence Berkeley Laboratory
University of California at Berkeley, Berkeley, CA 94720 USA

Running Head: Heavy Particle Pituitary Radiosurgery

Address correspondence and reprint requests to:

Richard P. Levy, M.D.

Donner Pavilion, Donner Laboratory

University of California at Berkeley

Berkeley, CA 94720

[1]This research was supported by the Office of Health and Environmental Research, U.S. Department of Energy Contract DE-AC03-76SF00098.

Abstract

Since 1954, 840 patients have been treated at Lawrence Berkeley Laboratory with stereotactic charged-particle radiosurgery of the pituitary gland. The initial 30 patients were treated with proton beams; the subsequent 810 patients were treated with helium-ion beams. In the great majority of the 475 patients treated for pituitary tumors, marked and sustained biochemical and clinical improvement was observed. Variable degrees of hypopituitarism developed in about one-third of patients treated solely with radiosurgery. In the earlier years of the program, 365 patients underwent radiosurgery to treat selected systemic diseases by inducing hypopituitarism. Focal temporal lobe necrosis and cranial nerve injury occurred in about 1% of patients who were treated with doses less than 230 Gy.

Key Words: heavy-charged particles, pituitary adenomas, pituitary irradiation, stereotactic radiosurgery

Introduction

In 1946, Wilson [1] proposed the therapeutic use of charged-particle beams, based on their unique physical characteristics. After completion of the 184-inch Synchrocyclotron at the University of California at Berkeley - Lawrence Berkeley Laboratory (UCB-LBL) in 1947 [2], Tobias et al [3,4,5] began the study of the biologic effects of narrow beams of protons, deuterons and helium ions, with emphasis on reaction to radiation injury in the brain. The first clinical trials using charged particles were begun in 1954 by Lawrence, Tobias and their colleagues [6,7,8,9] for the pituitary-hormone suppression treatment of patients with metastatic breast carcinoma. Since then, stereotactically directed focal charged-particle pituitary radiosurgery has been used at UCB-LBL to treat 840 patients (Table 1). The initial 30 patients were treated with plateau proton beams; thereafter, almost all patients were treated with plateau helium-ion irradiation, although selected patients with larger tumor volumes and more recent patients received Bragg peak helium-ion radiosurgery.

In the earlier years of the program, patients with various disorders underwent treatment to effect hormonal suppression of disease by induction of hypopituitarism; this included 183 patients with metastatic breast carcinoma and 169 patients with diabetic retinopathy, as well as selected patients with prostatic carcinoma and other adenohypophyseal hormone-responsive malignancies (Table 1) [6,7,8,9,10,11,12]. In 1958, the charged-particle radiosurgery program was expanded to include patients with endocrine and metabolic disorders of the pituitary gland, i.e., acromegaly, Cushing's disease, Nelson's syndrome, prolactin-secreting adenomas and chromophobe adenomas [8,11,13,14,15,16]. In the 441 patients with hormone-secreting tumors, the therapeutic goal has been to destroy or inhibit the growth of the pituitary tumor and control hormonal hypersecretion, while preserving a functional rim of tissue with normal hormone-secreting capacity, and minimizing neurologic injury [11,13,15]; an additional 34 patients with nonsecreting chromophobe adenomas were treated to alleviate sequelae of an expanding mass lesion (Table 1).

Methods

Physical Properties of Charged-Particle Beams

Charged-particle beams manifest several physical properties that can be exploited to place a high dose of radiation within a deeply-located intracranial target volume for stereotactic radiosurgery (Figure 1) [11,17]. These include: (1) an initial plateau region of uniform and relatively lower dose as the beam penetrates through matter, followed by a region of higher dose (the Bragg ionization peak), at the end of the range of the beam, which can be adjusted to conform to the length of the target, so that the entrance dose can be kept to a minimum; (2) a well-defined range that increases with the energy of the beam and can be modulated so that the beam stops at the distal edge of the target, resulting in little or no exit dose beyond the Bragg peak; and (3) very sharp lateral edges that can readily be made to conform to the projected cross-sectional contour of the target, so that little or no dose is absorbed by adjacent normal tissues.

Radiosurgery

Plateau Region: When charged-particle beams of sufficiently high energy, and hence greater depth of penetration, are available, radiosurgery can be performed with the plateau portions of the narrow beams, using several intersecting arcs. In this technique, the plateau ionization regions of the charged-particle beams pass through the entire brain and the Bragg peak regions occur distal to the patient [18]. The isodose contours attained with the plateau irradiation technique are quite sharply delineated (Figure 2), and usually approximate the dose distributions attained with the Bragg peak technique (see below); differences are minor for small target volumes (e.g., pituitary gland). With this technique, consideration of the tissue inhomogeneity normally encountered in the head is not important, but accurate stereotactic localization of the intracranial target volume and precise isocentric technique are essential. Stereotactic plateau-beam radiosurgery has been employed at UCB-LBL for irradiation of the pituitary gland since 1954 [11,18].

A beam delivery system was developed at the UCB-LBL 184-inch Synchrocyclotron using 230 MeV/amu helium ions in the plateau ionization region. Patient immobilization was effected by an integrated system, consisting of an individually fabricated thermoplastic mask, stereotactic frame and an isocentric stereotactic apparatus (ISAH) (Figure 3).

Dose-localization was assured within a precision of 0.1 to 0.3 mm [19]; continuous and discontinuous rotation about the isocenter was achieved in two of three orthogonal planes (Figure 3). The optimal treatment procedure ensured that the optic chiasm, hypothalamus, and outer portions of the sphenoid sinus received less than 10% of the central-axis pituitary dose (Figure 2) [18]. Until the introduction of high-resolution CT and MRI scanning, it was necessary to use pneumoencephalography and polytomography to define the precise location of the pituitary gland, optic chiasm, nerves and tracts, and the adnexae of the cavernous and sphenoid sinuses.

Treatment was delivered in six to eight fractions over 2 to 3 weeks in the first few years of the program, and in three or four fractions over 5 days subsequently. The dose to adjacent cranial nerves and temporal lobes was considered to be a limiting factor rather than dose to the pituitary gland; the medial aspect of the temporal lobe received 36 Gy during longer courses of therapy, and 30 Gy to the same region during shorter courses of treatment. As the dose fell off rapidly from the central axis, the dose to the periphery of larger pituitary targets (e.g., acromegalic tumors) was considerably less than the peripheral dose to smaller targets (e.g., Cushing's disease).

Bragg Peak: Each charged-particle beam can be directed stereotactically to place uniquely shaped three-dimensional high-dose regions precisely within the brain by adjusting the range, by spreading the Bragg peak, by introducing tissue-equivalent compensators, and by using an appropriately-shaped aperture [11,17]. Several entry angles are chosen so that the high-dose regions of the individual beams intersect within the target volume. This technique provides considerable flexibility of choice of beam direction for multiport stereotactic treatment planning for three-dimensional conformal therapy, with a much lower dose to immediately adjacent and intervening normal brain tissues, and complete protection of the largest proportion of the normal brain tissues. For helium, the relative biologic effectiveness (RBE) in the Bragg ionization peak is assumed to be approximately 1.3, based on *in vitro* and *in vivo* studies [20].

For Bragg peak pituitary irradiation, the plateau-beam delivery system described above

has been modified using 165 MeV/amu helium-ion beams at the LBL Bevatron. The tumor and its relationships to adjacent neural structures are defined on stereotactic MRI scans, and the radiosurgical target is delineated [11]. The radiosurgical treatment plan is designed to place higher dose in the tumor mass lying within the sella and lower dose in any tumor mass extending into extrasellar tissues.

Results

Hormone-Dependent Metastatic Carcinoma

Between 1954-1972, stereotactically directed proton (initial 26 patients) or helium-ion beams (157 cases) were used at LBL for pituitary ablation in 183 patients with metastatic breast carcinoma. Patients received 180 to 270 Gy stereotactic plateau helium-ion beam irradiation to the pituitary gland to control the malignant spread of carcinoma by effecting hormonal suppression through induction of hypopituitarism [6]. Treatment resulted in a 95% decrease in pituitary cellularity with connective tissue replacement within a few months. At lower doses, the magnitude of cellular loss was dependent on the dose to the periphery of the gland [18]. Many patients experienced long-term remissions. Eight cases of focal radiation necrosis (including asymptomatic necrosis found at autopsy) limited to the adjacent portion of the temporal lobe occurred, all from an earlier group of patients entered in a dose-searching protocol who had received higher doses to suppress pituitary function as rapidly as possible; clinical manifestations, including temporal lobe injury and transient extraocular palsies, occurred in only four of these patients [21].

Diabetic Retinopathy

Between 1958-1969, 169 patients with proliferative diabetic retinopathy received plateau helium-ion focal pituitary irradiation to control insulin- and growth hormone-dependent retinal angiogenesis. The first 30 patients were treated with 160 to 320 Gy delivered over 11 days to effect total pituitary ablation; the subsequent 139 patients underwent subtotal pituitary ablation with 80 to 150 Gy delivered over 11 days. Most patients had a 15-50% decrease in insulin requirements; this result occurred sooner in patients receiving higher

doses, but ultimately both patient groups had comparable insulin requirements. Fasting growth hormone levels and reserves were lowered within several months after irradiation. Moderate to good vision was preserved in at least one eye in 59 of 114 patients at 5 years after pituitary irradiation (J.H. Lawrence, unpublished). Of 169 patients treated, 69 patients (41%) ultimately required thyroid replacement and 46 patients (27%) required adrenal replacement. There were four deaths from complications of hypopituitarism. Focal temporal lobe injury was limited to an early group of patients that had received at least 230 Gy in order to effect rapid pituitary ablation in advanced disease; four patients in this high-dose group developed extraocular palsies. Neurologic injury was rare in those patients receiving doses less than 230 Gy (J.H. Lawrence, unpublished).

Pathologic Changes

Autopsies were performed on 15 patients who had been treated with plateau helium-ion irradiation of the pituitary [22]. Ten of these patients had been treated for progressive diabetic retinopathy with average doses of 116 Gy delivered in six fractions. All patients demonstrated progressive pituitary fibrosis. Five patients with eosinophilic adenomas received an average of 56 Gy in six fractions. These adenomas developed cystic cavitation at the site of the adenoma, suggesting greater radiosensitivity of the tumor than the surrounding normal anterior pituitary gland, which in turn proved to be more radiosensitive than the posterior pituitary gland. No radiation changes were found in the surrounding brain or cranial nerves (Figure 4).

Acromegaly

Stereotactic helium-ion irradiation has proven to be very effective as the treatment of acromegaly [8,11,13,14,15]. Maximum dose to the pituitary tumor in 318 patients treated ranged from 30 to 50 Gy, most often delivered in four fractions over 5 days. Marked clinical and biochemical improvement was observed in most patients within the first year. The mean serum growth hormone level decreased nearly 70% within 1 year, and continued to decrease thereafter (Figure 5). Normal levels were sustained during more than 10 years of follow-up. Comparable results were observed in 65 patients who were irradiated with

helium ions because of residual or recurrent metabolic abnormalities persisting after surgical hypophysectomy. Most of the treatment failures after helium-ion irradiation apparently resulted from inaccurate assessment of extrasellar tumor extension [15].

Cushing's Disease

Stereotactic helium-ion radiosurgery has been applied successfully to the treatment of Cushing's disease in 83 patients [8,11,13,14,15,16]. Mean basal cortisol levels and dexamethasone suppression testing returned to normal values within 1 year after treatment, and remained normal during more than 10 years of follow-up. The pituitary gland received doses ranging from 30 to 150 Gy, most often delivered in three or four daily fractions. All five teenage patients were cured by doses of 60 to 120 Gy without inducing hypopituitarism or neurologic sequelae; however, nine of 59 older patients relapsed or failed to respond to treatment. Of the nine treatment failures, seven occurred in the earlier group of 22 patients treated with 60 to 150 Gy in six alternate-day fractions; when the same doses were given in three or four daily fractions, 40 of 42 patients were successfully treated [15]. The marked improvement in response with reduced fractionation in this group of patients has helped provide the clinical rationale for single-fraction treatment with stereotactically directed beams of heavy-charged particles.

Nelson's Syndrome

Nelson's syndrome has been treated by helium-ion treatment in 17 patients, including six patients who had prior pituitary surgery, but persistent tumor or elevated serum ACTH levels [11,13,14,15]. Treatment dose and fractionation were comparable to that in the Cushing's disease group, i.e., 50 to 150 Gy in four fractions. All patients exhibited marked decrease in ACTH levels, but rarely to normal levels. However, all but one patient had radiologic evidence of local tumor control [13,14]. One patient who had presented with invasive tumor had progressive suprasellar extension following radiosurgery, and died postoperatively after transfrontal decompression.

Prolactin-Secreting Tumors

Serum prolactin levels were reduced in the great majority of a cohort of 23 patients with prolactin-secreting pituitary tumors following helium-ion radiosurgery. Of 20 patients followed 1 year after irradiation, 19 had a marked fall in prolactin level (12 to normal levels) [13,15]. Treatment dose and fractionation were comparable to that in the Cushing's disease and Nelson's syndrome groups, i.e., 50 to 150 Gy in four fractions. Helium-ion irradiation was the sole treatment in 17 patients; the remaining six patients were irradiated after surgical hypophysectomy had failed to provide complete or permanent improvement.

Complications of Pituitary-Tumor Radiosurgery

Variable degrees of hypopituitarism developed in about a third of the patients, as sequelae of attempts at subtotal destruction of pituitary function, although endocrine deficiencies were rapidly corrected in most patients with appropriate hormonal replacement therapy. Diabetes insipidus has not been observed in any pituitary patients treated with helium-ion irradiation [15].

Complications in 318 acromegalic patients treated with helium-ion irradiation were relatively few and limited almost exclusively to those patients who had received prior photon treatment. Of seven patients who had previously undergone unsuccessful photon irradiation, three patients subsequently developed focal and readily-controlled seizures due to limited temporal lobe necrosis; three patients developed mild or transient extraocular palsies; two patients had partial field deficits. Thereafter, previously irradiated patients were excluded from the protocol [21]. Temporal lobe injury, but no cranial nerve dysfunction, occurred in only two of 283 patients treated solely with plateau helium-ion irradiation; both were cases treated in the initial series, and who had received higher radiation doses than were used in later years [15].

Neurologic sequelae of stereotactic radiosurgical treatment have been infrequent in the Cushing's disease group of patients. One patient developed asymptomatic visual field deficits 18 months after treatment. Two patients developed rapid progression of ACTH-secreting pituitary adenomas (i.e., Nelson's syndrome) following bilateral adrenalectomy that had been performed after helium irradiation failed to control the tumor growth ade-

quately. Two patients developed transient partial third nerve palsies 6 to 7 years following helium-ion treatment [15].

Discussion and Conclusions

Stereotactic heavy-charged-particle helium-ion radiosurgery of the pituitary gland has proven to be a highly effective method of treatment for a variety of endocrine and metabolic hormone-dependent conditions, alone or in combination with surgical hypophysectomy. Since 1954, 840 patients have received stereotactically directed focal plateau or Bragg peak helium-ion pituitary irradiation at UCB-LBL to suppress pituitary function and/or control tumor growth. In the great majority of patients with pituitary tumors, this method has resulted in reliable control of neoplastic growth and suppression of hypersecretion, while generally preserving a rim of functional pituitary tissue. Variable degrees of hypopituitarism resulted in a number of cases, but such endocrine deficiencies and associated metabolic dysfunction were readily corrected with appropriate hormone supplemental therapy.

Clinical protocols for stereotactic helium-ion Bragg peak radiosurgery for pituitary microadenomas and recurrences following surgery are in progress at LBL, to make use of the uniquely advantageous dose-distribution and dose-localization properties inherent in the Bragg ionization peak. Improved anatomic resolution now possible with multiplanar MRI and CT scanning has made possible better localization of pituitary microadenomas and adjacent neural structures, and more accurate assessment of extrasellar tumor extension. These recent neuroradiologic advances should result in improved cure and control rates for pituitary tumors and related intracranial disorders, decreased treatment sequelae, and a decrease in the number of treatment failures previously found to have resulted from inaccurate assessment of tumor extension.

References

[1] Wilson RR: Radiological use of fast protons. Radiology 1946;47:487–491.

[2] Brobeck WM, Lawrence EO, MacKenzie KR, McMillan EM, Serber R, Sewall DC, Simpson KM, Thornton RL: Initial performance of the 184-inch cyclotron of the University of California. Phys Rev 1947;71:449–450.

[3] Tobias CA, Anger HO, Lawrence JH: Radiologic use of high energy deuterons and alpha particles. Am J Roentgenol Radium Ther Nucl Med 1952;67:1–27.

[4] Tobias CA, Roberts JE, Lawrence JH, Low-Beer BVA, Anger HO, Born JL, McCombs R, Huggins CB: Irradiation hypophysectomy and related studies using 340-MeV protons and 190-MeV deuterons; in Proceedings of the International Conference on the Peaceful Uses of Atomic Energy. Geneva, 1955, pp 95–106.

[5] Tobias CA, Van Dyke DC, Simpson ME, Anger HO, Huff RL, Koneff AA: Irradiation of the pituitary of the rat with high energy deuterons. Am J Roentgenol Radium Ther Nucl Med 1954;72:1–21.

[6] Lawrence JH: Proton irradiation of the pituitary. Cancer 1957;10:795–798.

[7] Lawrence JH, Born JL, Tobias CA, Carlson R, Sangalli F, Welch G: Clinical and metabolic studies in patients after alpha particle subtotal or total hypophysectomy; in Medicine in Japan in 1959. Proceedings of the 15th General Assembly of the Japan Medical Congress. Tokyo, 1959, pp 859–862.

[8] Lawrence JH, Tobias CA, Born JL, Wang CC, Linfoot JA: Heavy-particle irradiation in neoplastic and neurologic disease. J Neurosurg 1962;19:717–722.

[9] Tobias CA, Lawrence JH, Born JL, McCombs RK, Roberts JE, Anger HO, Low-Beer BVA, Huggins CB: Pituitary irradiation with high-energy proton beams: A preliminary report. Cancer Res 1958;18:121–134.

[10] Lawrence JH, Tobias CA, Linfoot JA, Born JL, Gottschalk A, Kling RP: Heavy particles, the Bragg curve and suppression of pituitary function in diabetic retinopathy. Diabetes 1963;12:490–501.

[11] Levy RP, Fabrikant JI, Frankel KA, Phillips MH, Lyman JT: Charged-particle radiosurgery of the brain. Neurosurg Clin North Am 1990;1:955-990.

[12] Linfoot JA, Born JL, Garcia JF, Manougian E, Kling RP, Chong CY, Tobias CA, Carlson RA, Lawrence JH: Metabolic and ophthalmological observations following heavy particle pituitary suppressive therapy in diabetic retinopathy; in Goldberg MF, Fine SL (eds): Symposium on the Treatment of Diabetic Retinopathy. Airlie House, Warrenton, VA (U S Public Health Service Publication No. 1890), Arlington, 1968, pp 277–289.

[13] Lawrence JH: Heavy particle irradiation of intracranial lesions; in Wilkens RH, Rengachary SS (eds): Neurosurgery. New York, McGraw-Hill, 1985, pp 1113–1132.

[14] Lawrence JH, Linfoot JA: Treatment of acromegaly, Cushing disease and Nelson syndrome. West J Med 1980;133:197–202.

[15] Linfoot JA: Heavy ion therapy: Alpha particle therapy of pituitary tumors; in Linfoot JA (ed): Recent Advances in the Diagnosis and Treatment of Pituitary Tumors. New York, Raven Press, 1979, pp 245–267.

[16] Linfoot JA, Lawrence JH, Born JL, Tobias CA: The alpha particle or proton beam in radiosurgery of the pituitary gland for Cushing's disease. N Engl J Med 1963;269:597–601.

[17] Levy RP, Fabrikant JI, Frankel KA, Phillips MH, Lyman JT: Stereotactic heavy-charged-particle Bragg peak radiosurgery for the treatment of intracranial arteriovenous malformations in childhood and adolescence. Neurosurgery 1989;24:841–852.

[18] Tobias CA: Pituitary radiation: Radiation physics and biology; in Linfoot JA (ed): Recent Advances in the Diagnosis and Treatment of Pituitary Tumors. New York, Raven Press, 1979, pp 221–243.

[19] Lyman JT, Chong CY: ISAH: A versatile treatment positioner for external radiation therapy. Cancer 1974;34:12–16.

[20] Blakely EA, Ngo FQH, Curtis SB, Tobias CA: Heavy-ion radiobiology: Cellular studies; in Lett JT (ed): Advances in Radiation Biology. New York, Academic Press, 1984, vol 11, pp 295–389.

[21] McDonald LW, Lawrence JH, Born JL, Lyman JT: Delayed radionecrosis of the central nervous system; in Lawrence JH (ed): Semiannual Report. Biology and Medicine. Donner Laboratory and Donner Pavilion. Fall 1967 (UCRL Report No. 18066), Berkeley, Regents of the University of California, 1967, pp 173–192.

[22] Woodruff KH, Lyman JT, Lawrence JH, Tobias CA, Born JL, Fabrikant JI: Delayed sequelae of pituitary irradiation. Hum Pathol 1984;15:48–54.

Figure 1: The plateau and Bragg ionization curves are shown for an unmodulated charged-particle beam of helium ions (225 MeV/u). As the beam of charged particles enters an absorbing material, the resulting ionization (or dose) is nearly constant in the initial *plateau* portion of the beam path, increases rapidly in the *Bragg ionization peak* and then decreases precipitously to negligible levels in a rapidly tapering *tail.*

Figure 2: Stereotactic irradiation with the plateau portion of a charged-particle beam (helium ions, 230 MeV/u) designed for pituitary irradiation at the University of California at Berkeley - Lawrence Berkeley Laboratory 184-inch Synchrocyclotron; the three-dimensional isodose contours (90% to 10% isodose curves) for one octant of the radiation field used to treat pituitary adenomas are illustrated. The dose fall-off from 90% to 10% occurs in less than 4 mm in the frontal plane. The technique produces very favorable dose distributions for the treatment of small intracranial lesions. (From Tobias CA: Pituitary radiation: Radiation physics and biology; in Linfoot JA (ed): Recent Advances in the Diagnosis and Treatment of Pituitary Tumors. New York, Raven Press, 1979, pp 221-243.)

Figure 3: Stereotactic frame and mask immobilization technique as part of the irradiation stereotactic apparatus for humans (ISAH) system for stereotactic multiport helium-ion irradiation developed for pituitary irradiation at the University of California at Berkeley - Lawrence Berkeley Laboratory 184-inch Synchrocyclotron. The ISAH immobilization system is designed to place the unmodulated Bragg peak within 0.1 mm in water medium in coplanar and noncoplanar entry angles relative to three planar (x, y, z) coordinates. The mask is a rigid transparent polystyrene heat-vacuum molded unit which has been tailored to each individual patient; the system is an integral part of the overall immobilization facility, and is designed in coordination with the charged-particle beam delivery system. The immobilization technique has provided satisfactory immobilization for stereotactic charged-particle radiosurgery in over 1,200 patients. (From Levy RP, Fabrikant JI, Frankel KA, Phillips MH, Lyman JT: Charged-particle radiosurgery of the brain. Neurosurg Clin North Am 1990;1:955–990.)

Figure 4: Pathologic autopsy specimen of the pituitary gland of a patient with metastatic

breast carcinoma 14 years after stereotactic helium-ion radiosurgery for hormonal suppression. The precise demarcation of normal tissue, the central coagulative necrosis and the peripheral rim of preserved functioning pituitary gland epithelium are readily identified. (From Fabrikant JI, Levy RP, Phillips MH, Frankel KA, Lyman JT: Neurosurgical applications of ion beams. Nucl Instrum Methods Phys Res 1989;B40/41:1376-1384.)

Figure 5: Changes in plasma human growth hormone (HGH) levels in 234 patients with acromegaly one or more years after stereotactic helium-ion (230 MeV/u) plateau radiosurgery at the University of California at Berkeley - Lawrence Berkeley Laboratory 184-inch Synchrocyclotron. At the top of the graph are the numbers of patients used to calculate the median plasma levels for each time interval following radiosurgery. Fourteen patients did not have preradiosurgery HGH measurements, but their HGH levels determined 4 to 18 years after radiosurgery are comparable with those of the other 220 patients. Excluded from this series were 63 patients who had undergone prior pituitary surgery and 5 patients whose preradiosurgery growth hormone levels were less than 5 ng/ml. The 20 patients in the series who subsequently underwent pituitary surgery or additional pituitary irradiation were included until the time of the second procedure. (From Lawrence JH: Heavy particle irradiation of intracranial lesions; in Wilkins RH, Rengachary SS (eds): Neurosurgery. New York, McGraw-Hill, 1985, pp 1113-1132.)

Table 1
CHARGED-PARTICLE RADIOSURGERY OF THE PITUITARY GLAND AT UCB-LBL [a]
1954 to Present

Disorder	Patients Treated	
Pituitary Tumors (total)	475	
Acromegaly		318
Cushing's Disease		83
Nelson's Syndrome		17
Prolactin-secre		23
Nonfunctioning Adenomas		34
Pituitary Suppression (total)	365	
Diabetic Retinopathy		169
Breast Cancer		183
Prostate Cancer		3
Ophthalmopathy		3
Other		7
Total	840	

[a] UCB-LBL: University of California at Berkeley - Lawrence Berkeley Laboratory

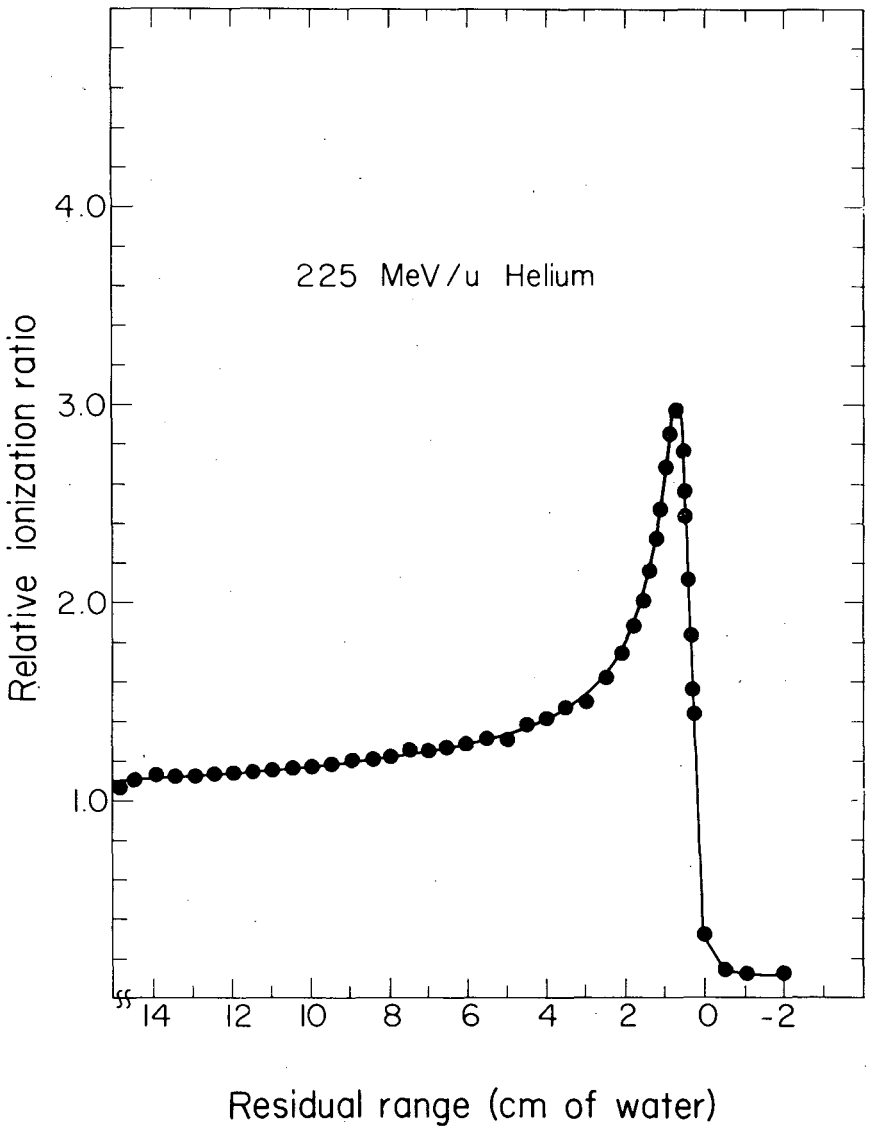

XBL 833-8919-A

Figure 1

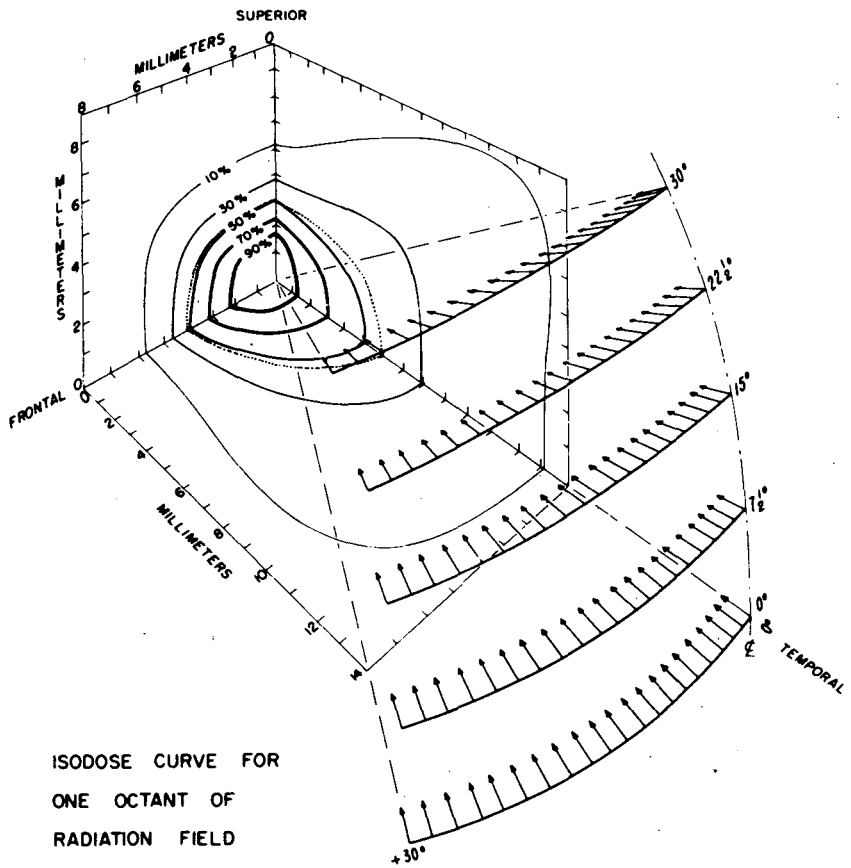

Figure 2



JHL 2897A

Figure 3

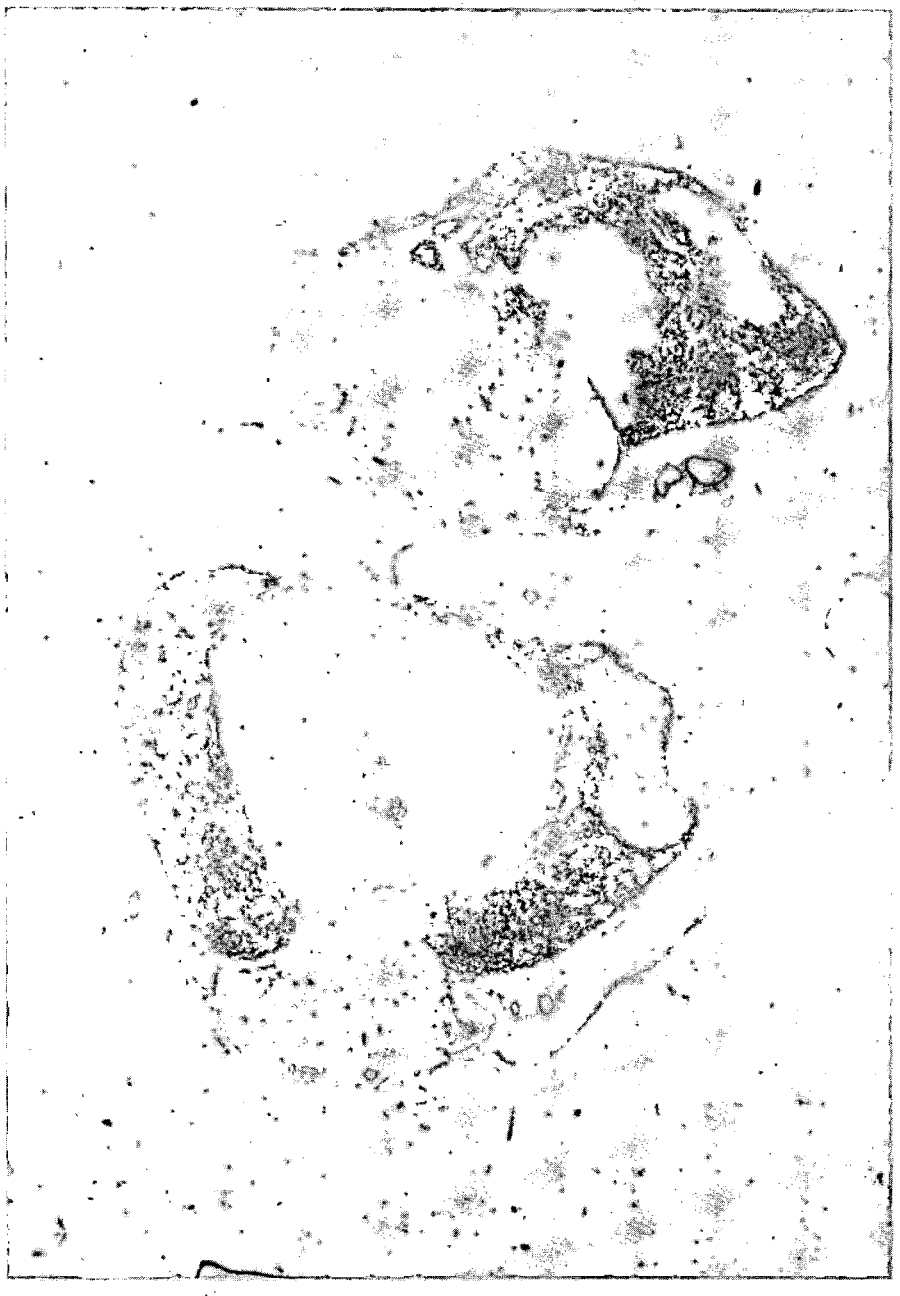

Figure 4

CBB 762-1381

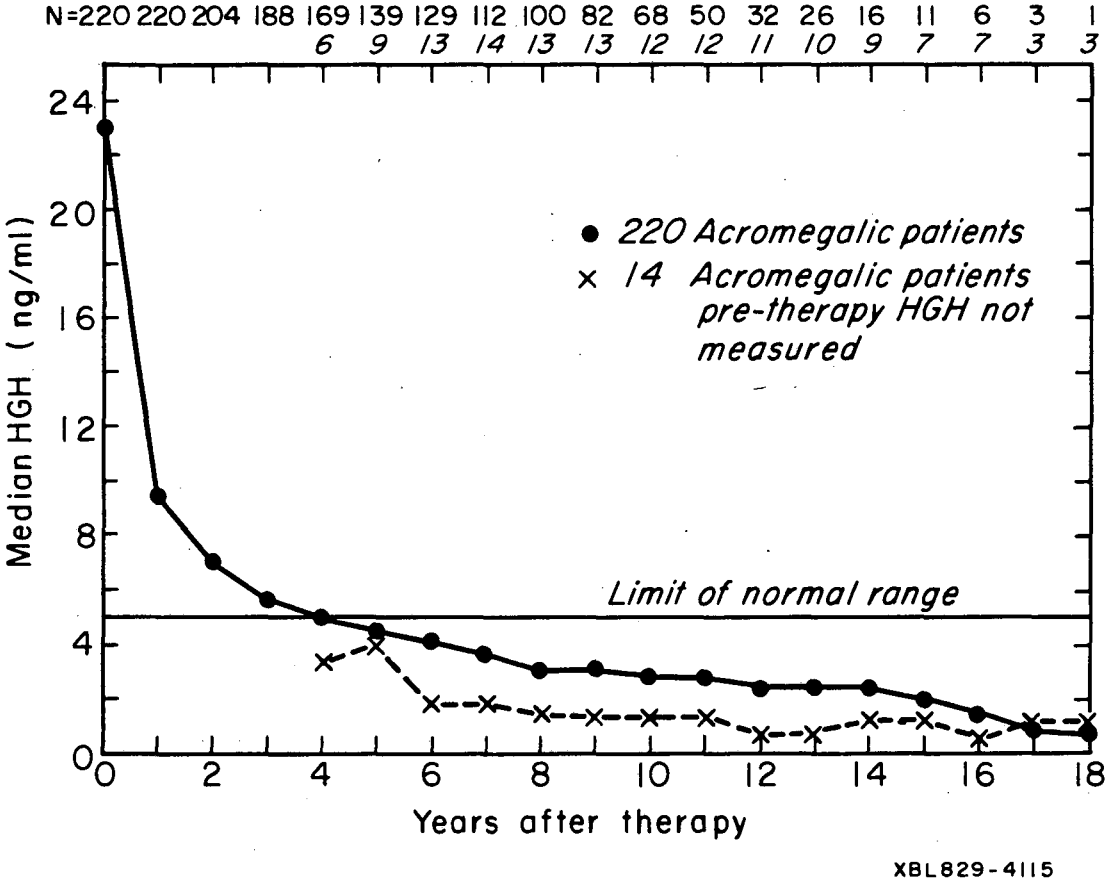
N=220 220 204 188 169 139 129 112 100 82 68 50 32 26 16 11 6 3 1
6 9 13 14 13 13 12 12 11 10 9 7 7 3 3
Median HGH (ng/ml)
24
20
16
12
8
4
0
● 220 Acromegalic patients
× 14 Acromegalic patients pre-therapy HGH not measured
Limit of normal range
0 2 4 6 8 10 12 14 16 18
Years after therapy
XBL829-4115

Figure 5

LAWRENCE BERKELEY LABORATORY
UNIVERSITY OF CALIFORNIA
INFORMATION RESOURCES DEPARTMENT
BERKELEY, CALIFORNIA 94720